Normal EKG

EKG

- EKG kağıdı üzerinde her biri 0.04 sn. olan küçük kareler ile 0.20 sn. olan büyük kareler bulunur.
- Kareler boyuna olarak değerlendirildiğinde her küçük kare 1 mm veya 0.1 milivolt (mV), her büyük kare ise 5 mm veya 0.5 mV'tur.
- EKG'nin kayıt hızı pratikte saniyede 25 mm olarak belirlenir

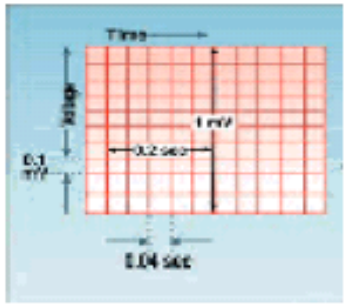

P DALGASI

- Atriyal depolarizasyon dalgasıdır.
- En iyi II ve V1 derivasyonlarda görülür.
- Genellikle I, II ve III derivasyonlarda pozitif; aVR derivasyonunda ise negatiftir.
- Yüksekliği < 2.5 mm
- Süresi < 0.12 sn

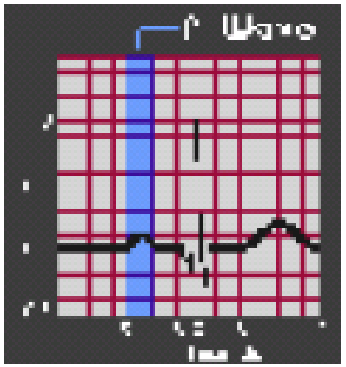

PR ARALIĞI

- SAN'dan çıkan uyarının intraatriyal, AV nodal ve His-Purkinje iletim sisteminden geçtiği sürenin toplamıdır.
- Normal P-R aralığı yaş ilerledikçe uzar, kalp hızı arttıkça da kısalır.
- Süresi: 0.12-0.20 sn
- izoelektrik hatti olusturur.

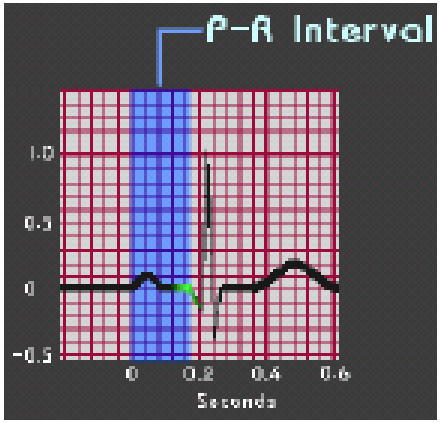

QRS KOMPLEKSİ

Ventriküllerin depolarizasyonunu yansıtır.

- Süresi: < 0.11 sn
- Q dalgası yüksekliği, eşlik eden R dalgasının ¼'ünden fazla olmamalı ve süresi 0.04 sn'nin altında olmalıdır.

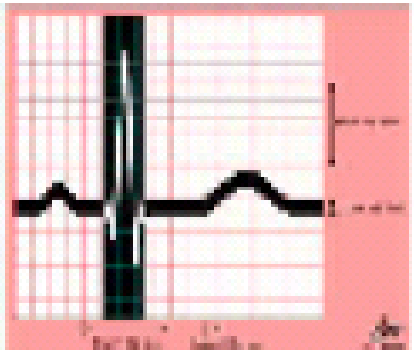

S-T SEGMENTİ

QRS kompleksinin sonundan T dalgasının başlangıcına kadar olan süredir.

- Her iki ventrikül tam olarak aktive olduğunda kaydedilen çizgidir. Normalde düzdür.
- ST segmentinin şeklinin tanısal değeri vardır, ancak süresi önemli değildir.
- İzoelektrik çizgiden 1 mm'den fazla (aşağı veya yukarı doğru) yer değiştirmemelidir.

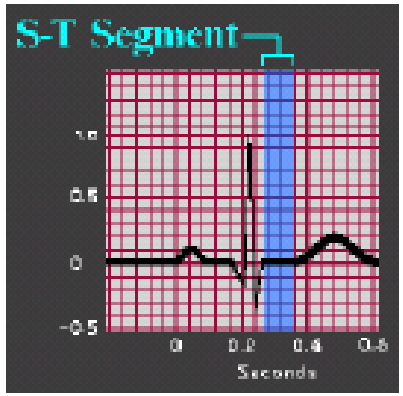

T DALGASI

Ventriküllerin repolarizasyonunu yansıtır.

- Amplitüdü genel olarak R dalgasının 1/8 – 2/3'ü kadardır.
- Amplitüdü V2 veya V3 derivasyonunda en büyüktür

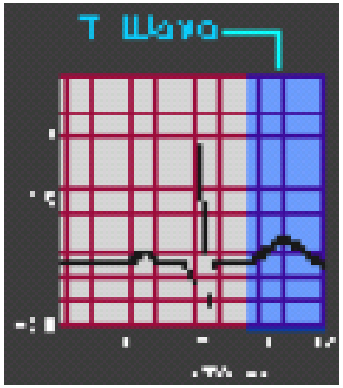

Normal EKG Nasıl Olmalıdır ?

- Kalp Hızı: 60-100/dakika
- Ritim düzenli olmalıdır
- P dalgası: aynı derivasyonda yer alan tüm p dalgalarının morfolojisi aynı olmalıdır
- Her p dalgasından önce bir QRS kompleksi, Her QRS kompleksinden önce bir p dalgası gelmelidir
- PR aralığı: 0.12-0.20sn olmalıdır, trase üzerindeki tüm PR aralıkları eşit olmalıdır.
- QRS kompleksi: Genişliği <0.11sn olmalı, patolojik Q dalgası olmamalıdır
- ST segmenti: izoelektirik hattan >1mm çökme veya elevasyon göstermemelidir.
- T dalgası: AVR, D3, V1-V2 dışındaki derivasyonlarda negatif yönde olmamalıdır

Tanınız nedir ?

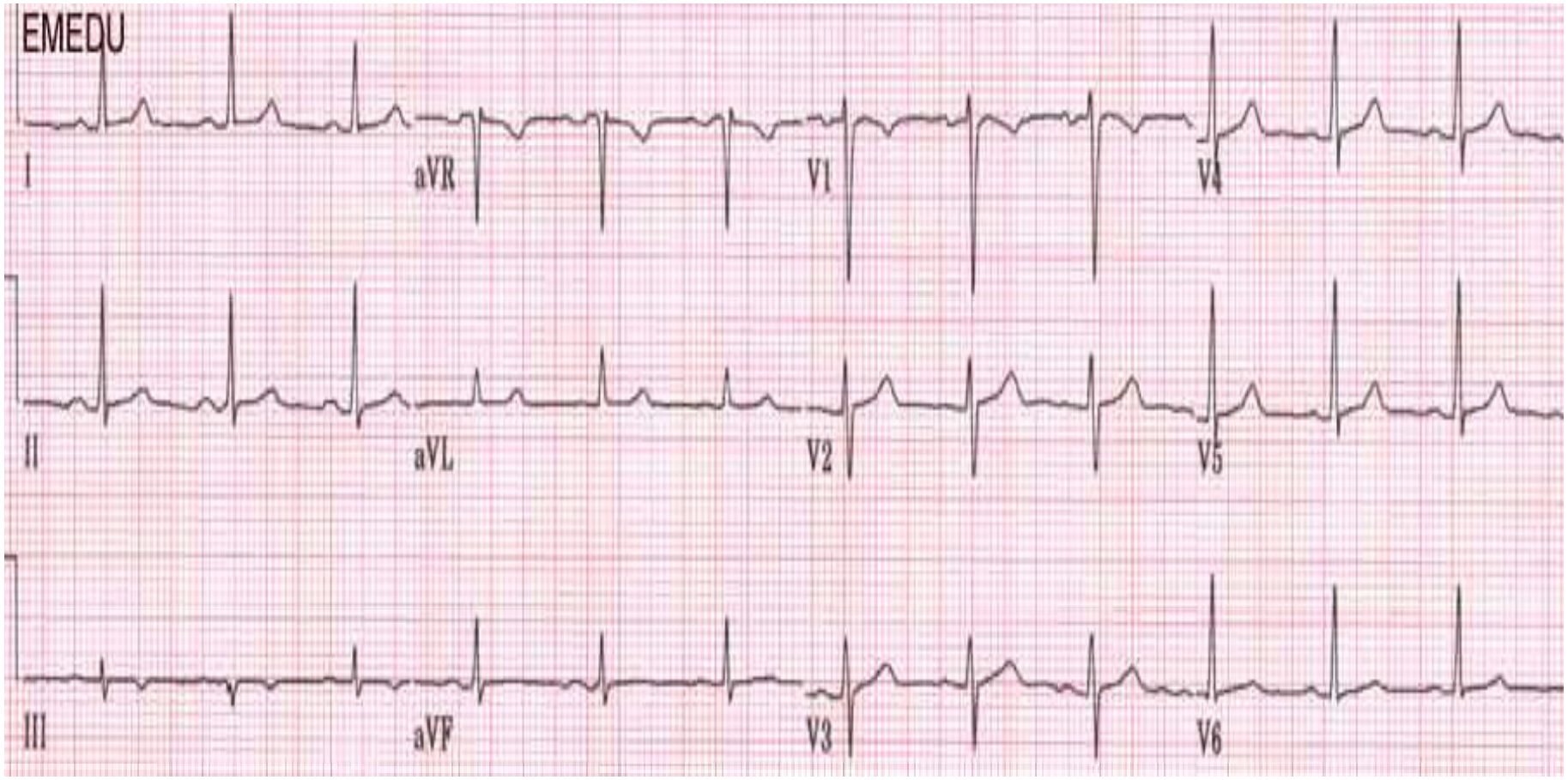

Normal sinüs ritmi

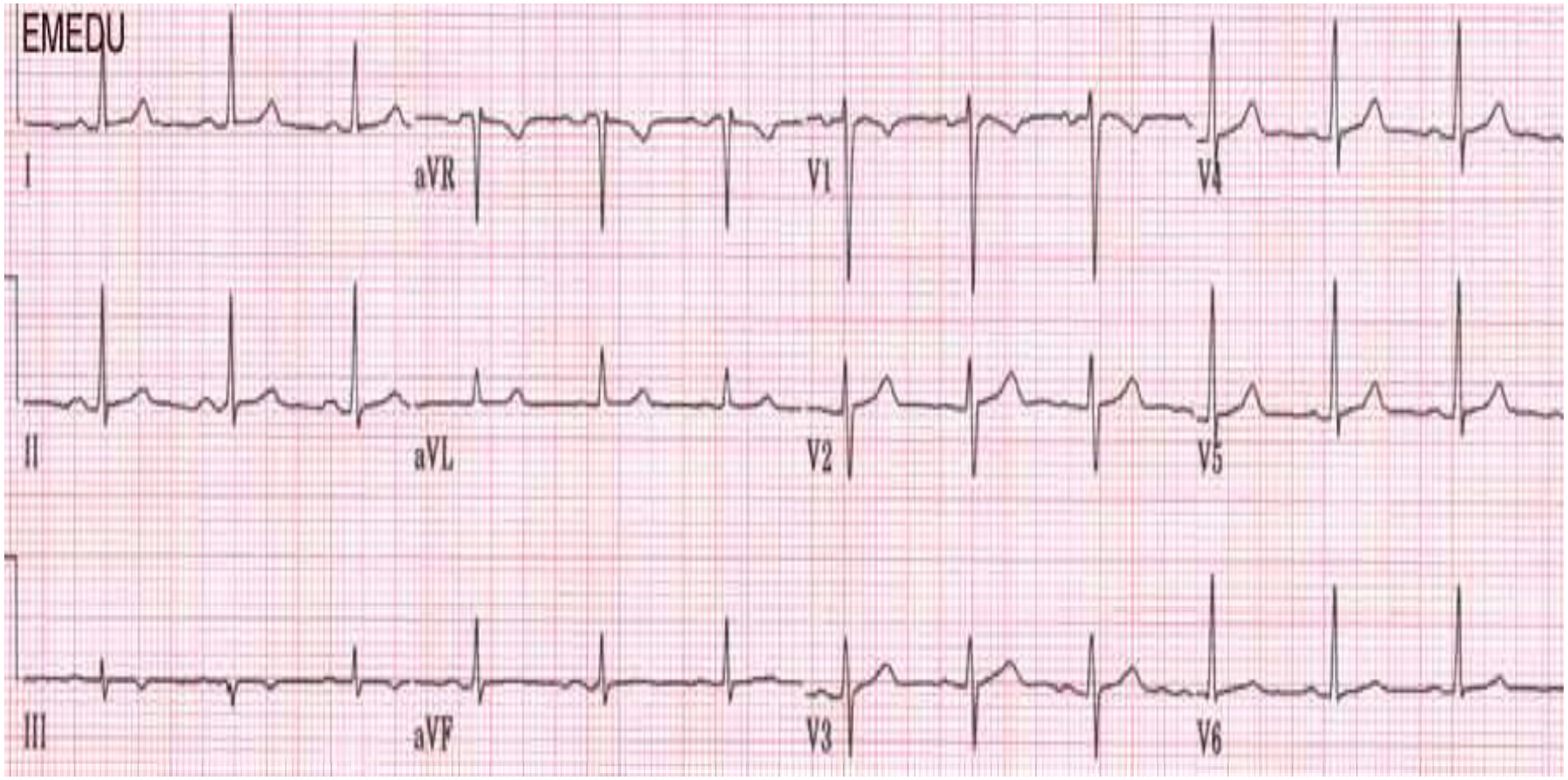

Tanınız nedir ?

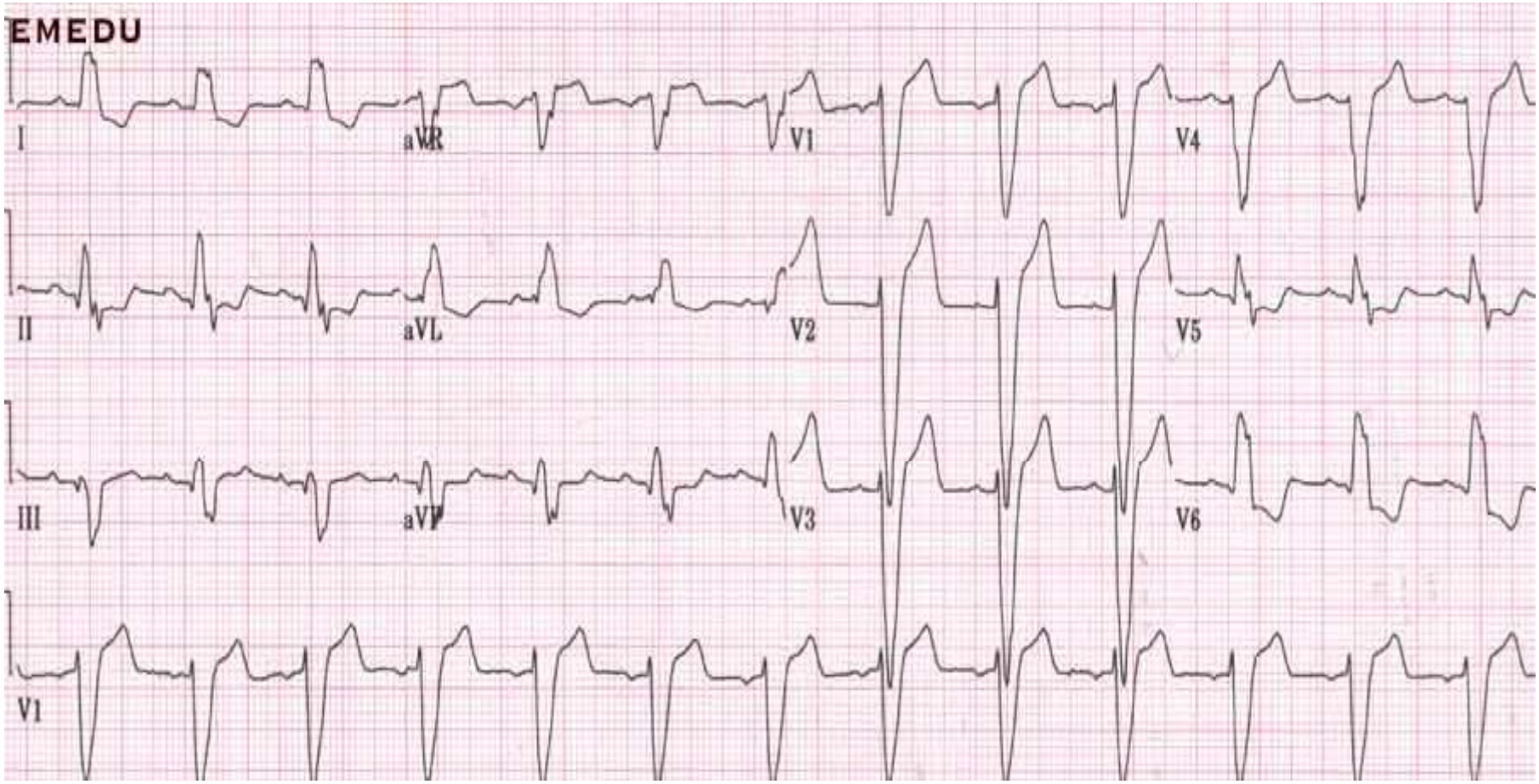

Komplet Sol Dal bloğu

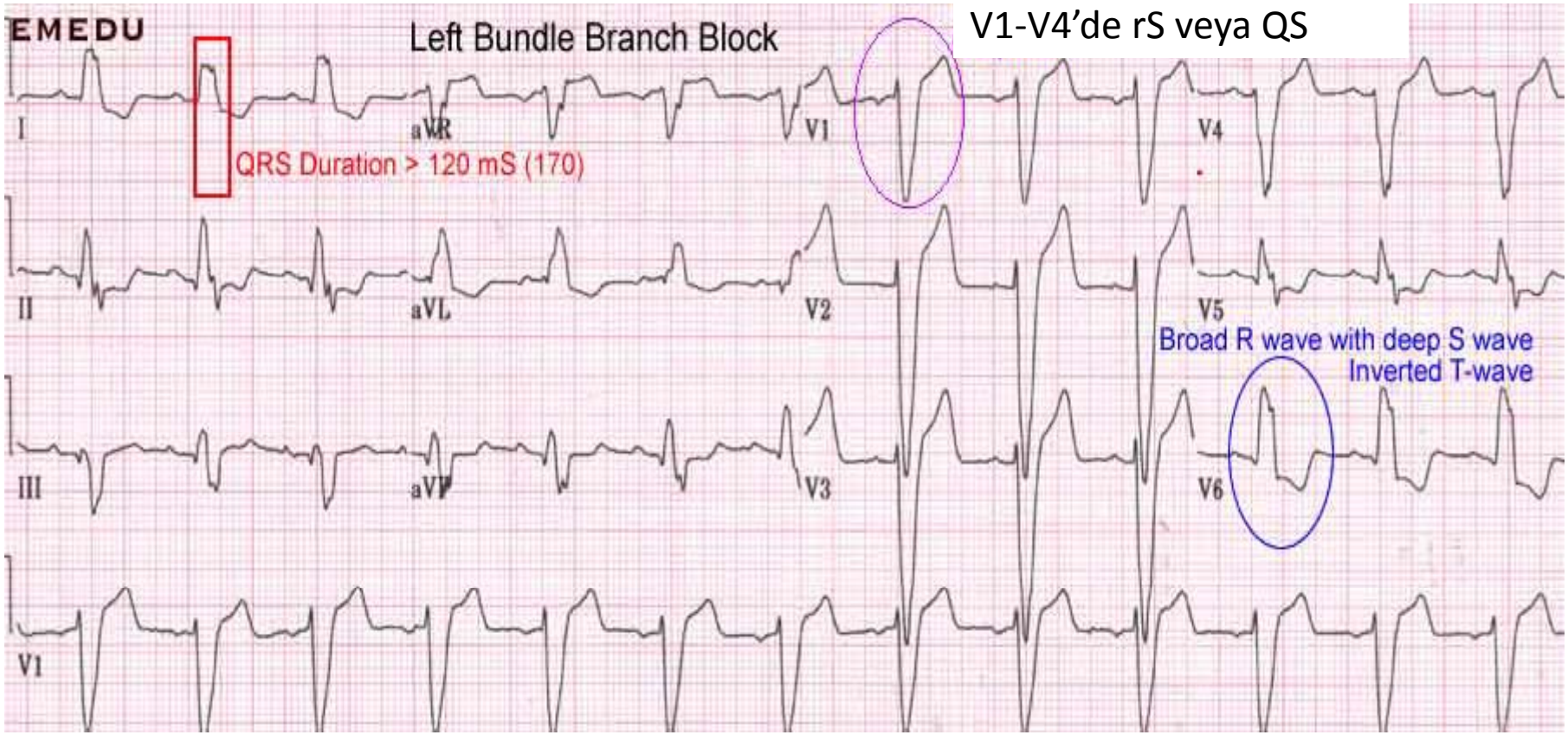

Tanınız nedir ?

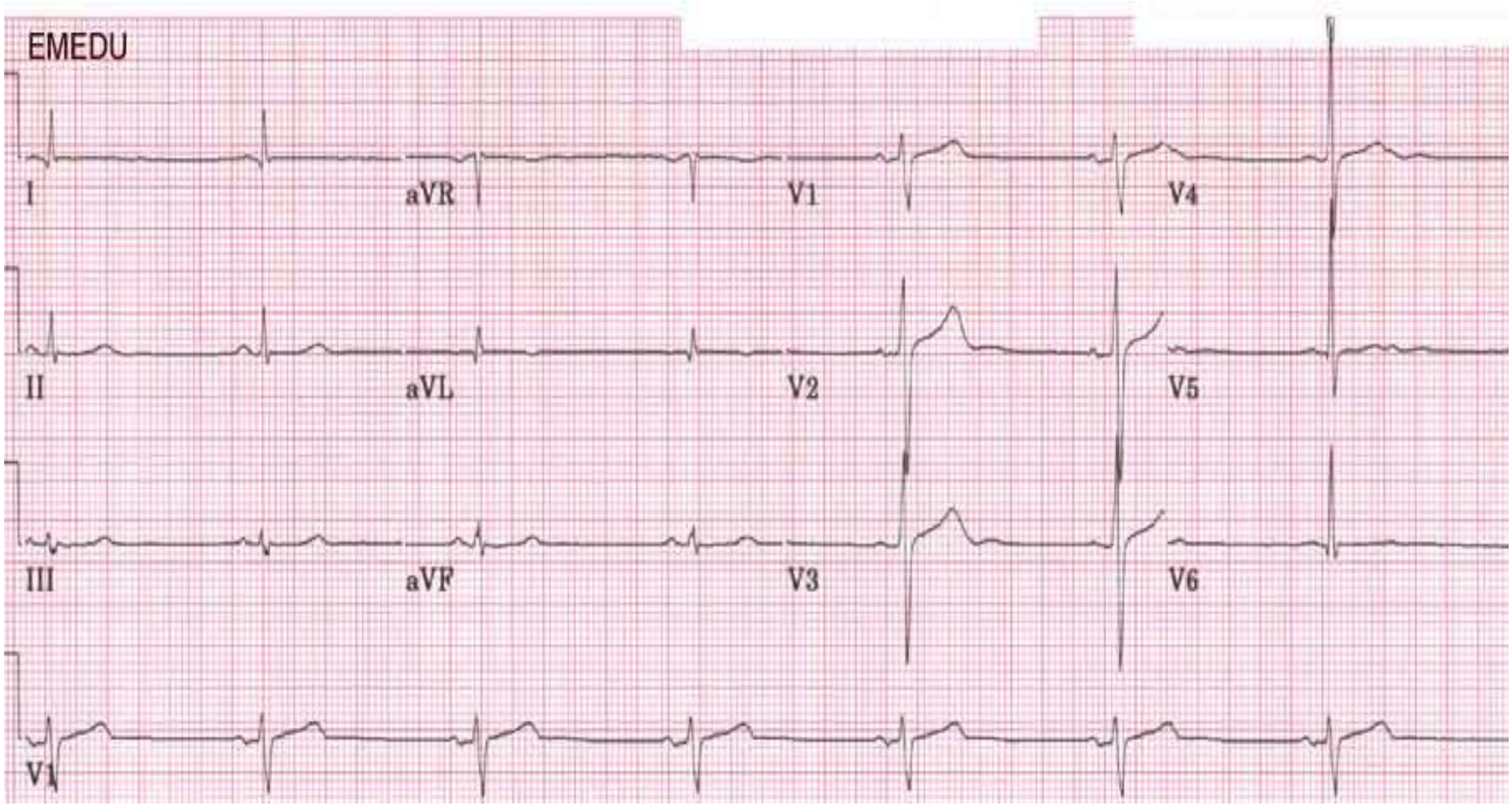

Sinüzal Bradikardi

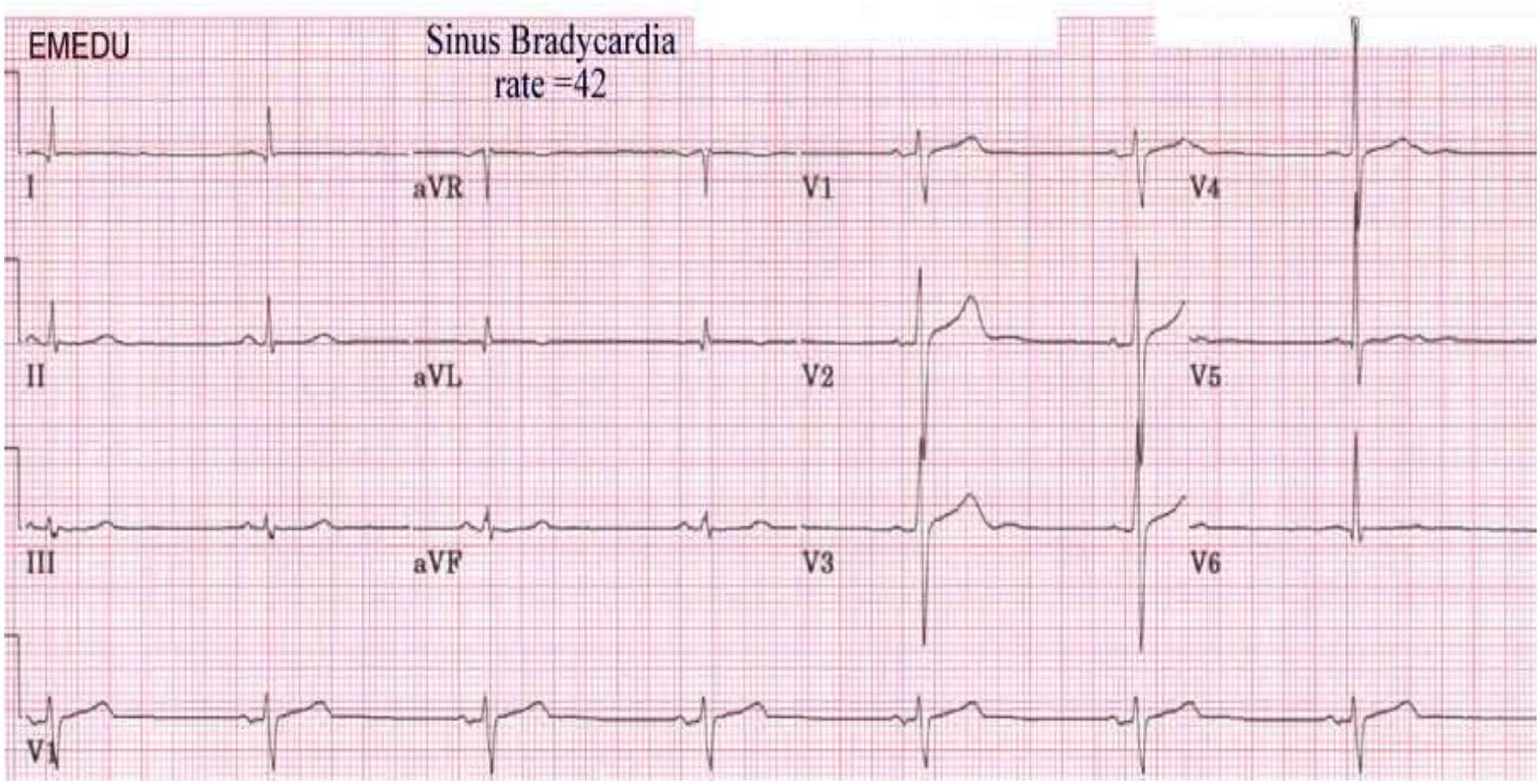

Tanınız nedir ?

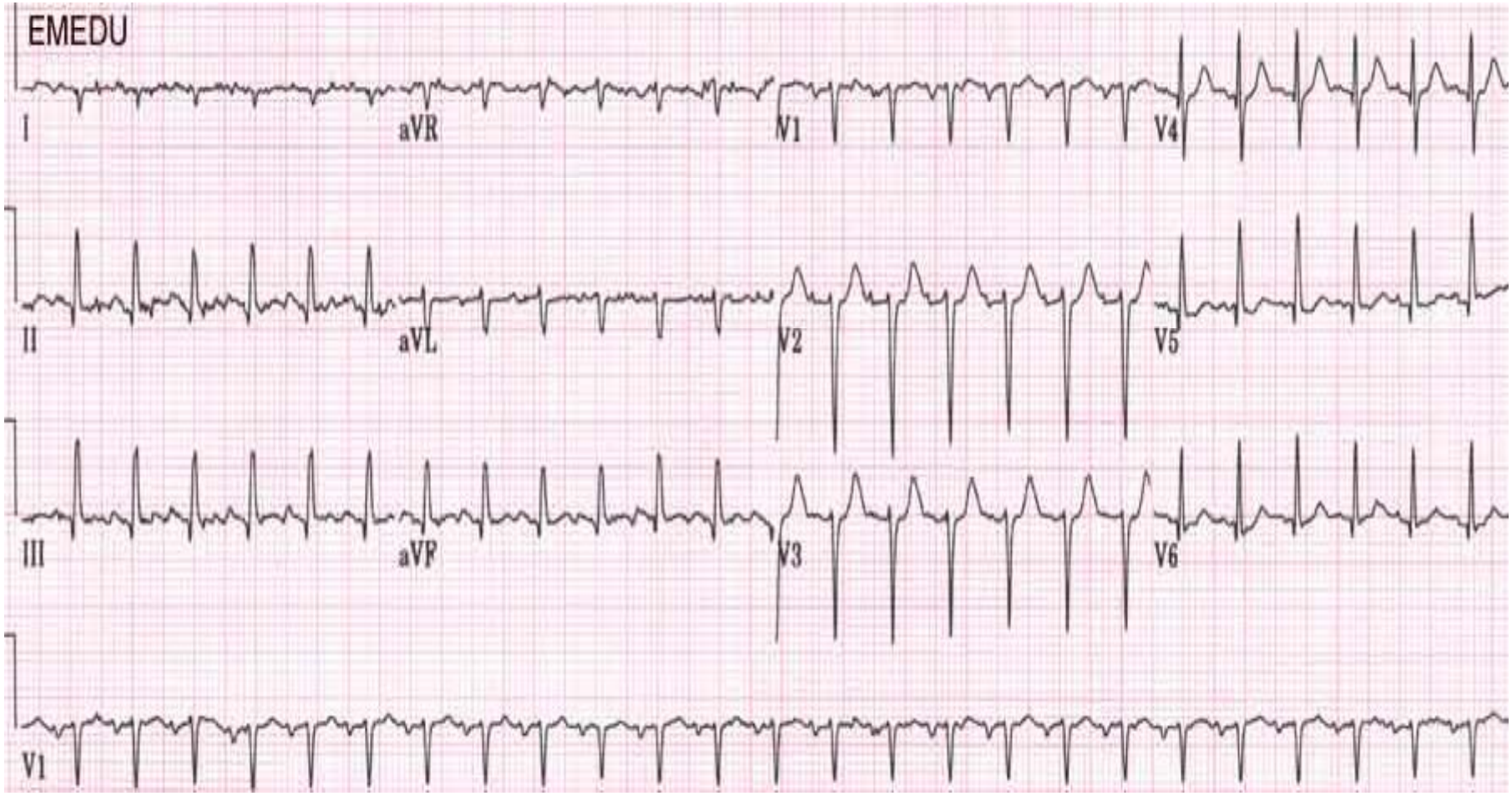

Sinüzal Taşikardi

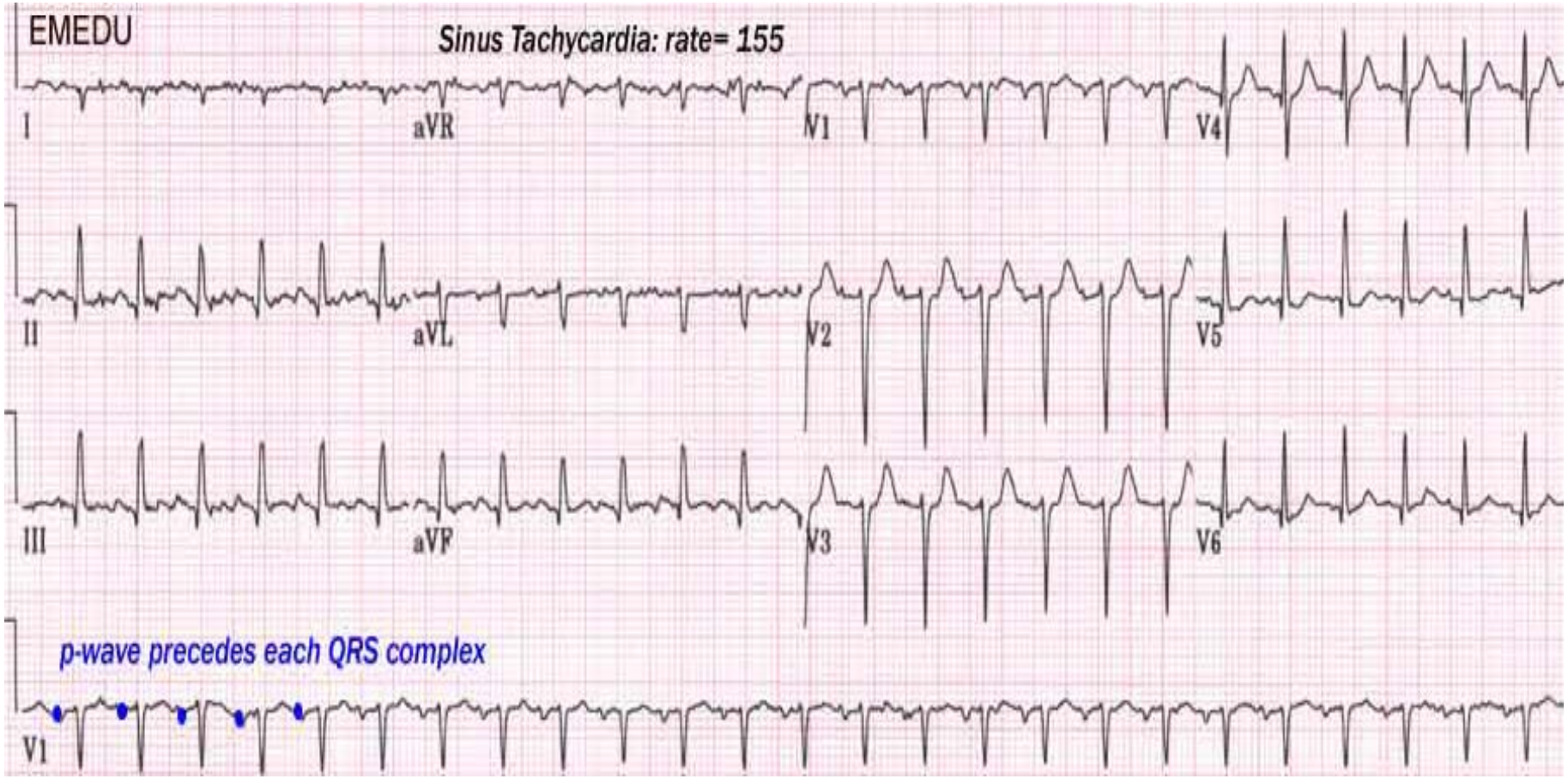

Tanınız nedir ?

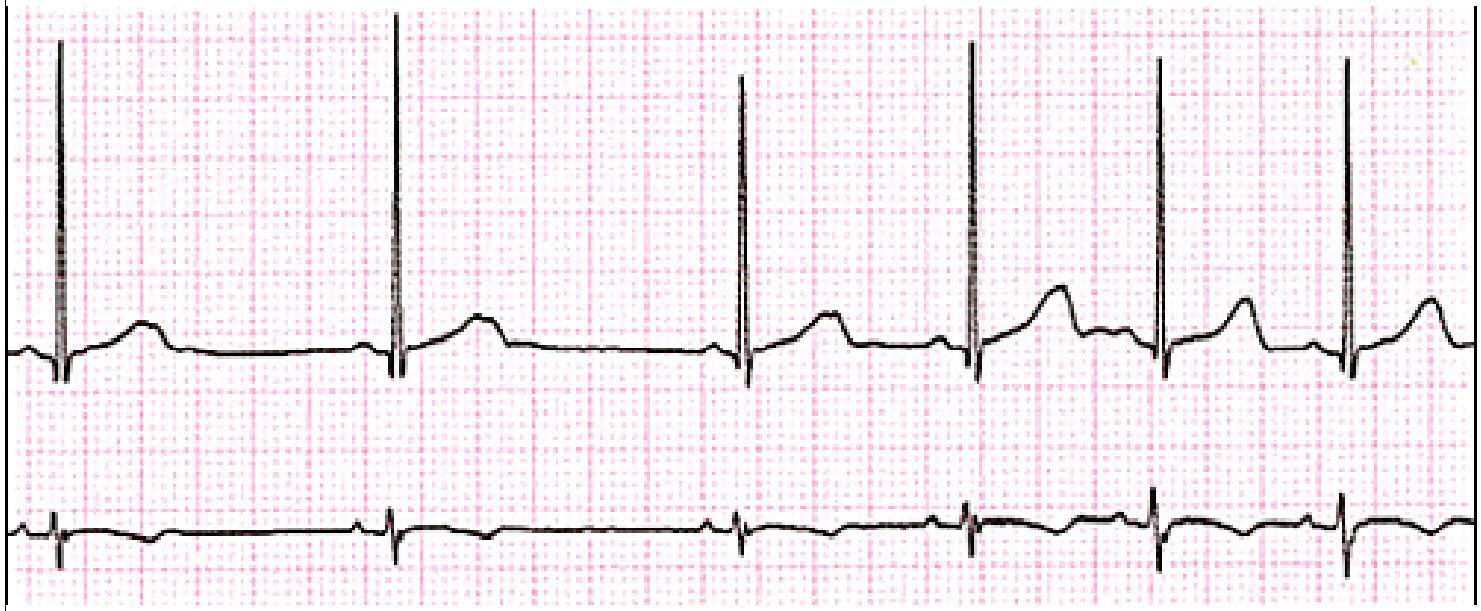

Sinüzal aritmi

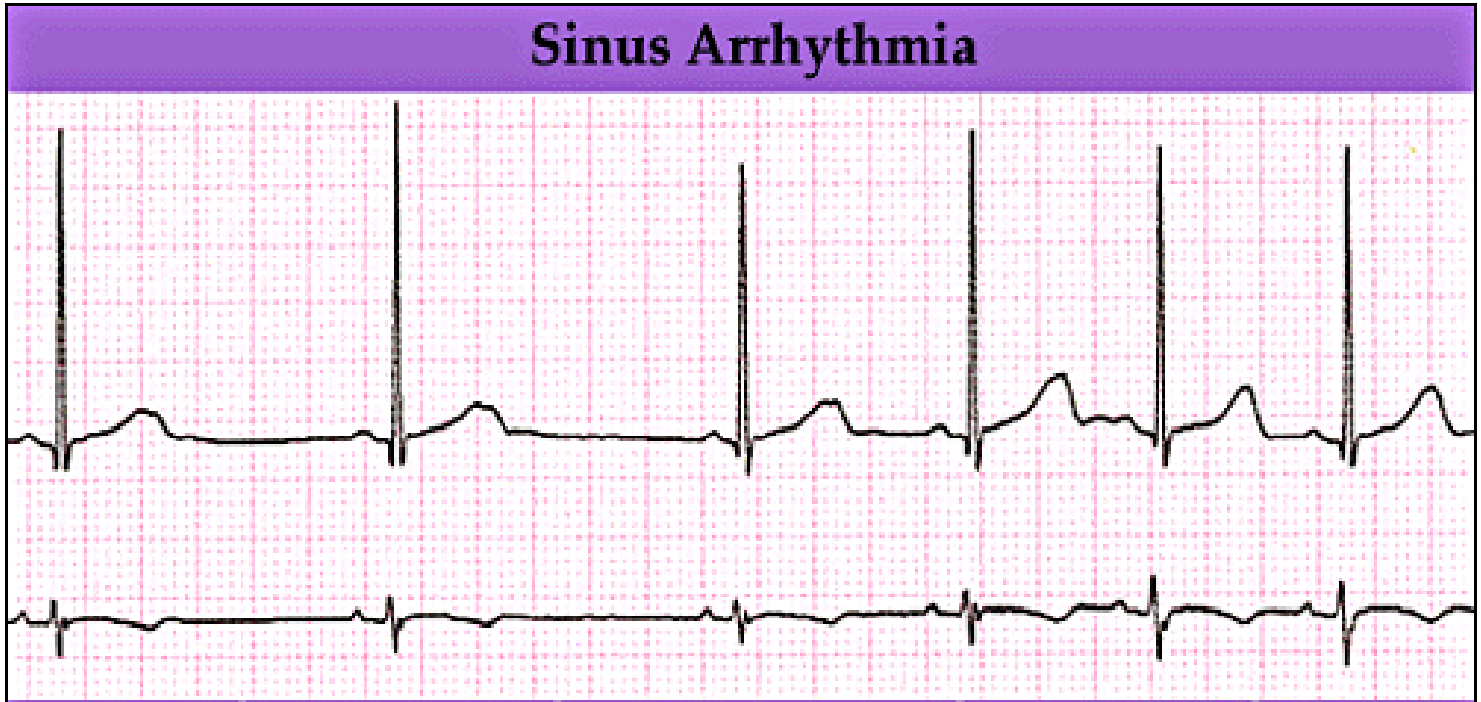

Heart Rate	Rhythm	P Wave	PR interval (in seconds)	QRS (in seconds)
Usually 60-100 bpm	Irregular	Before each QRS, identical	.12 to .20	<.12

Tanınız nedir ?

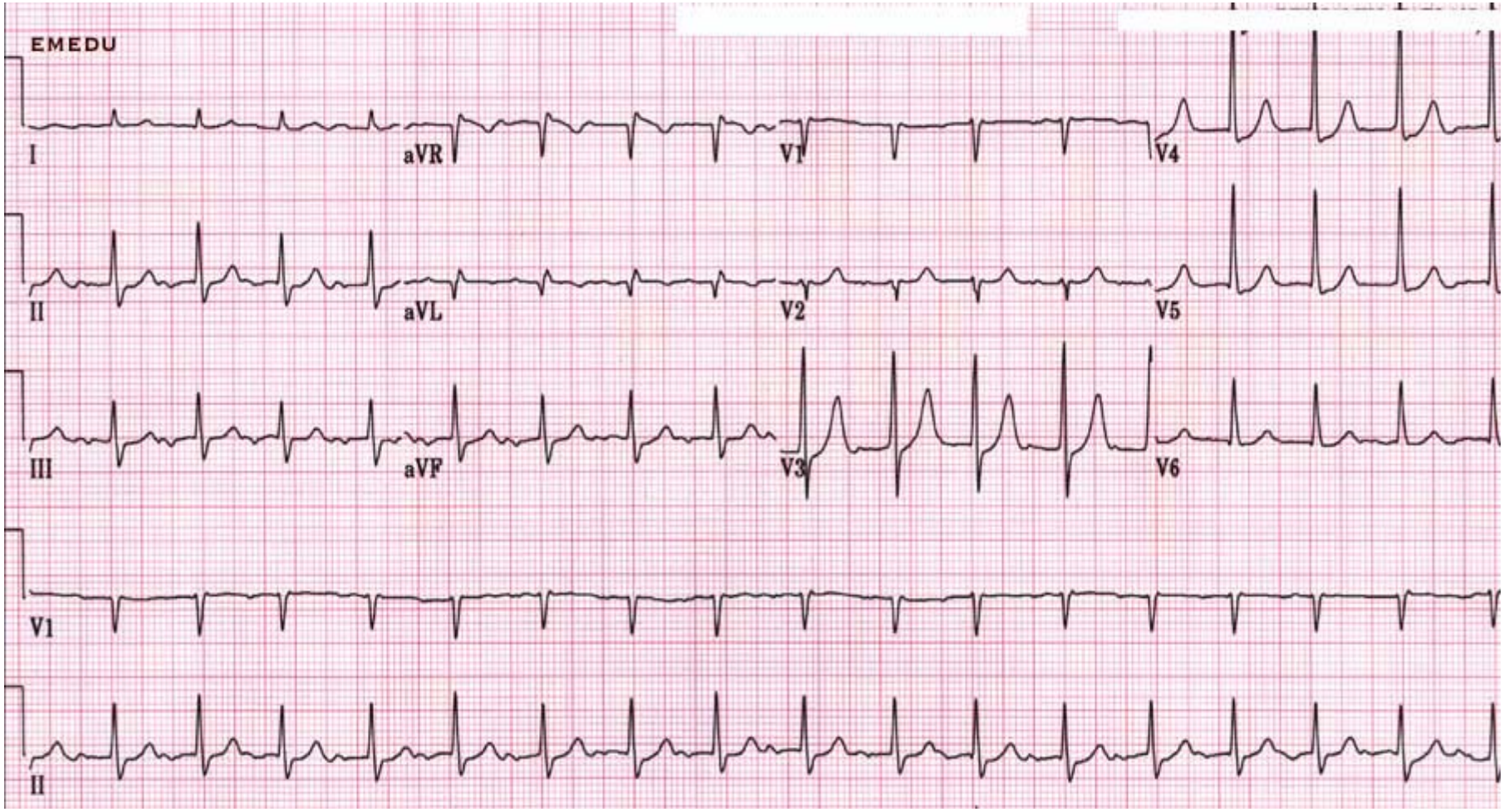

Sinüzal Bradikardi , 1° AV Blok

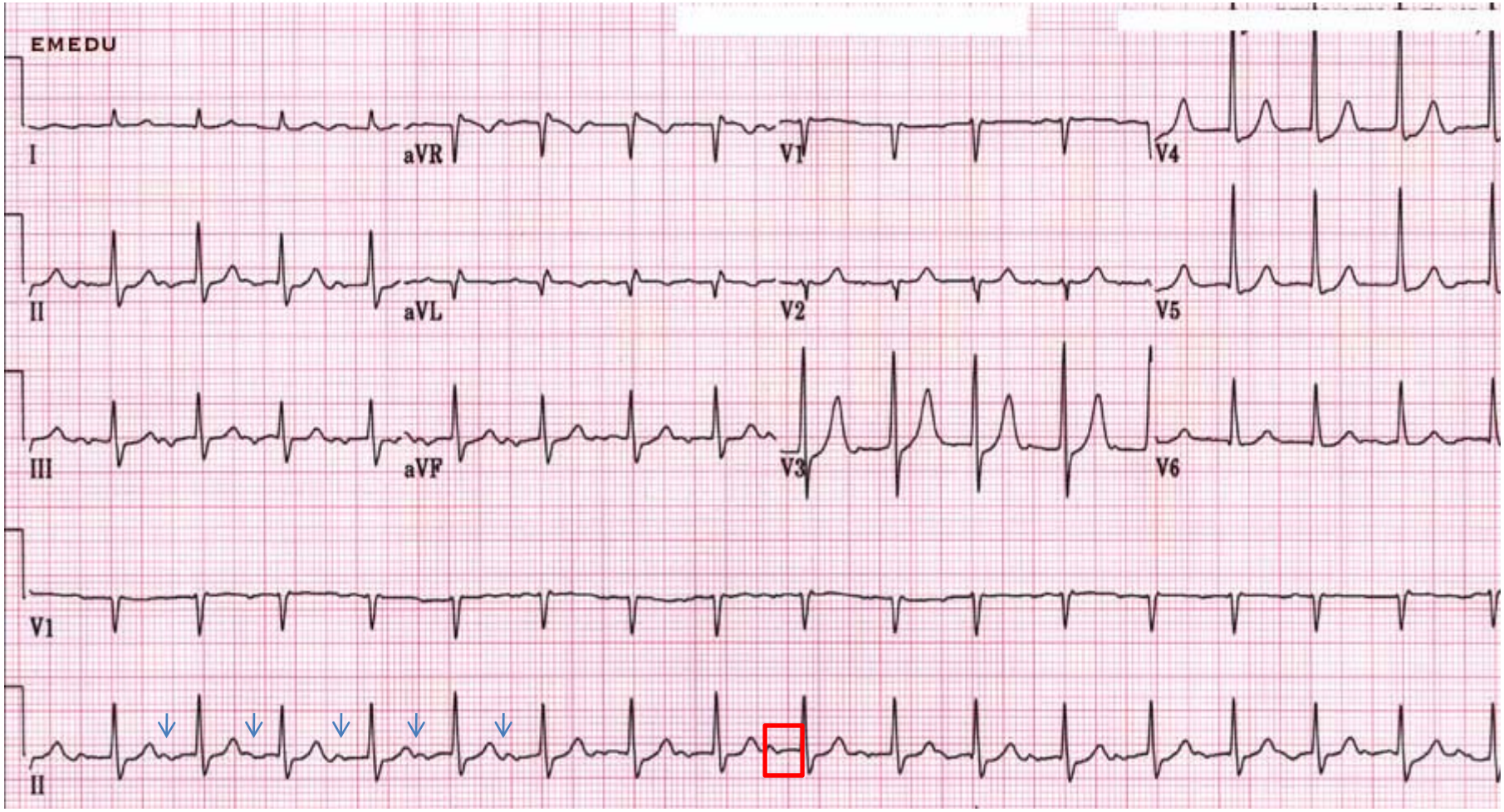

Tanınız nedir ?

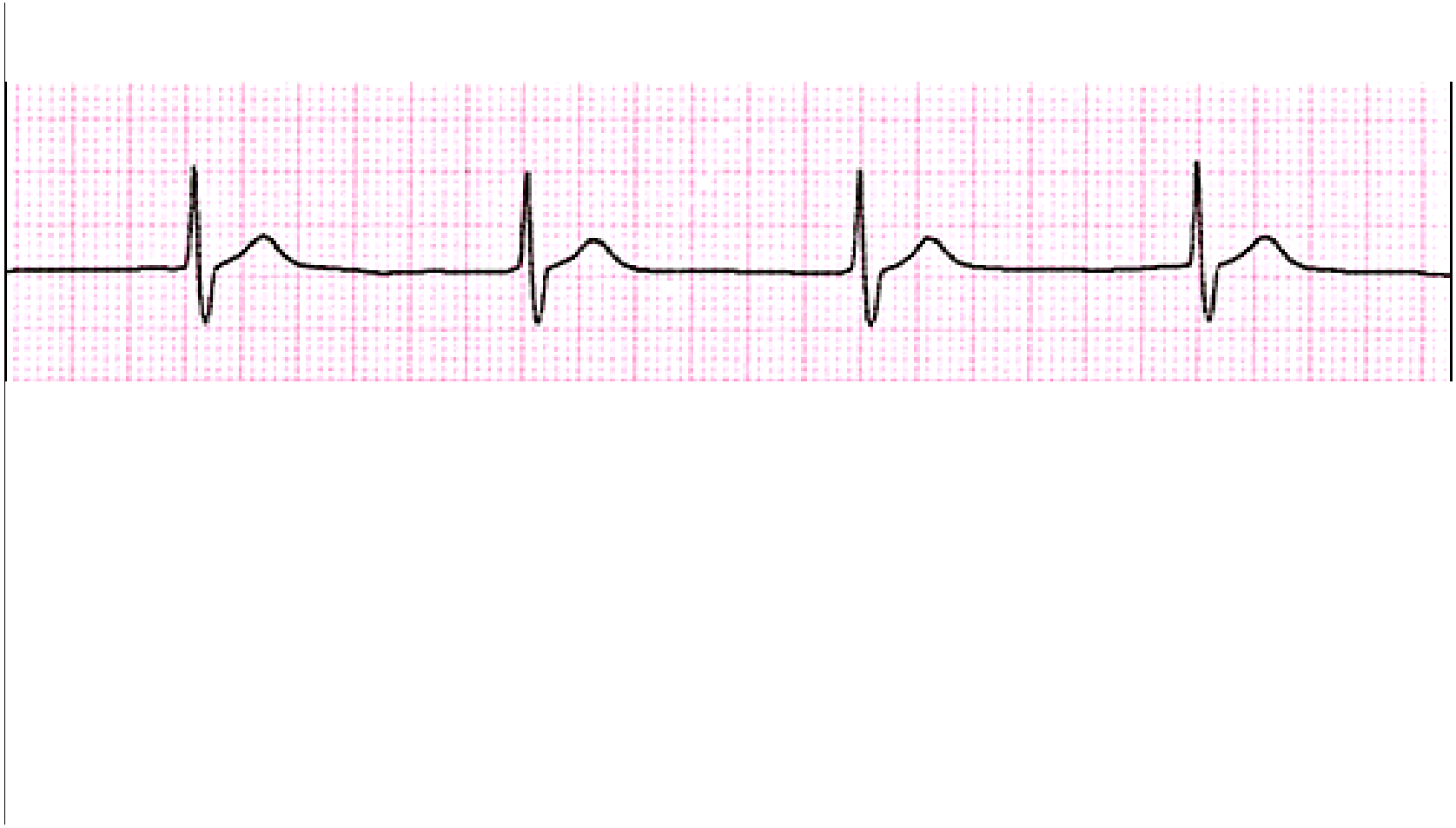

Nodal Kaçış Ritmi

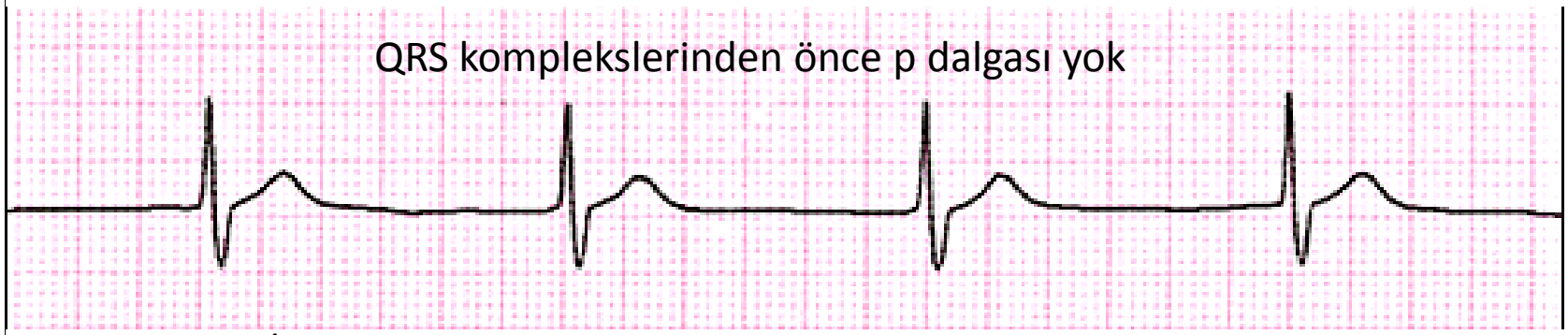

Hız: 50/dk

Tanınız nedir ?



Sinüzal arrest (pause)

Sinus Arrest

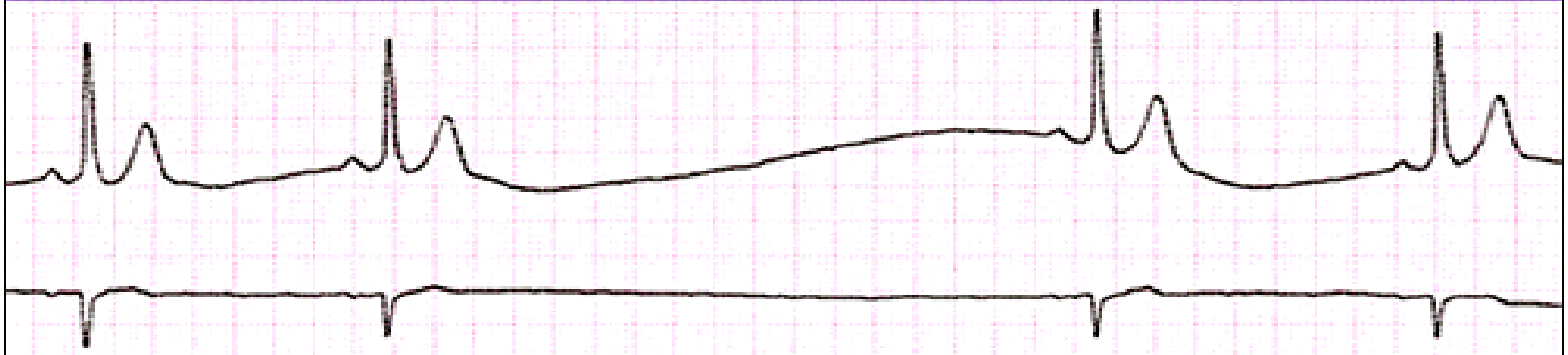

Please note: trace and grid have been reduced in size

Heart Rate	Rhythm	P Wave	PR interval (in seconds)	QRS (in seconds)
N/A	Irregular	Before each QRS identical. New rhythm begins after a pause. The P to P interval is disturbed.	.12 to .20	<.12

Tanınız nedir ?

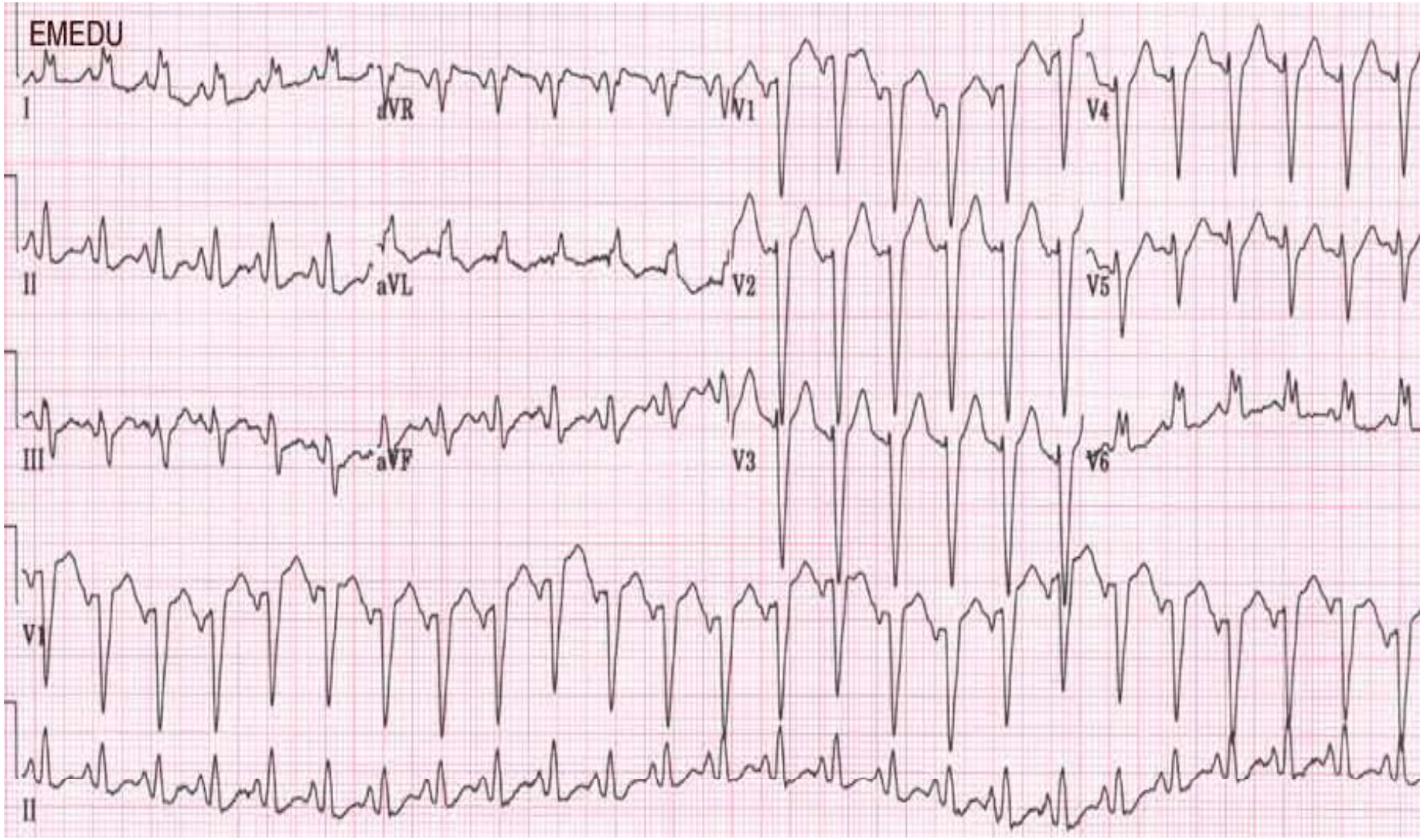

Sinüs Taşikardisi + Sol Dal Bloğu

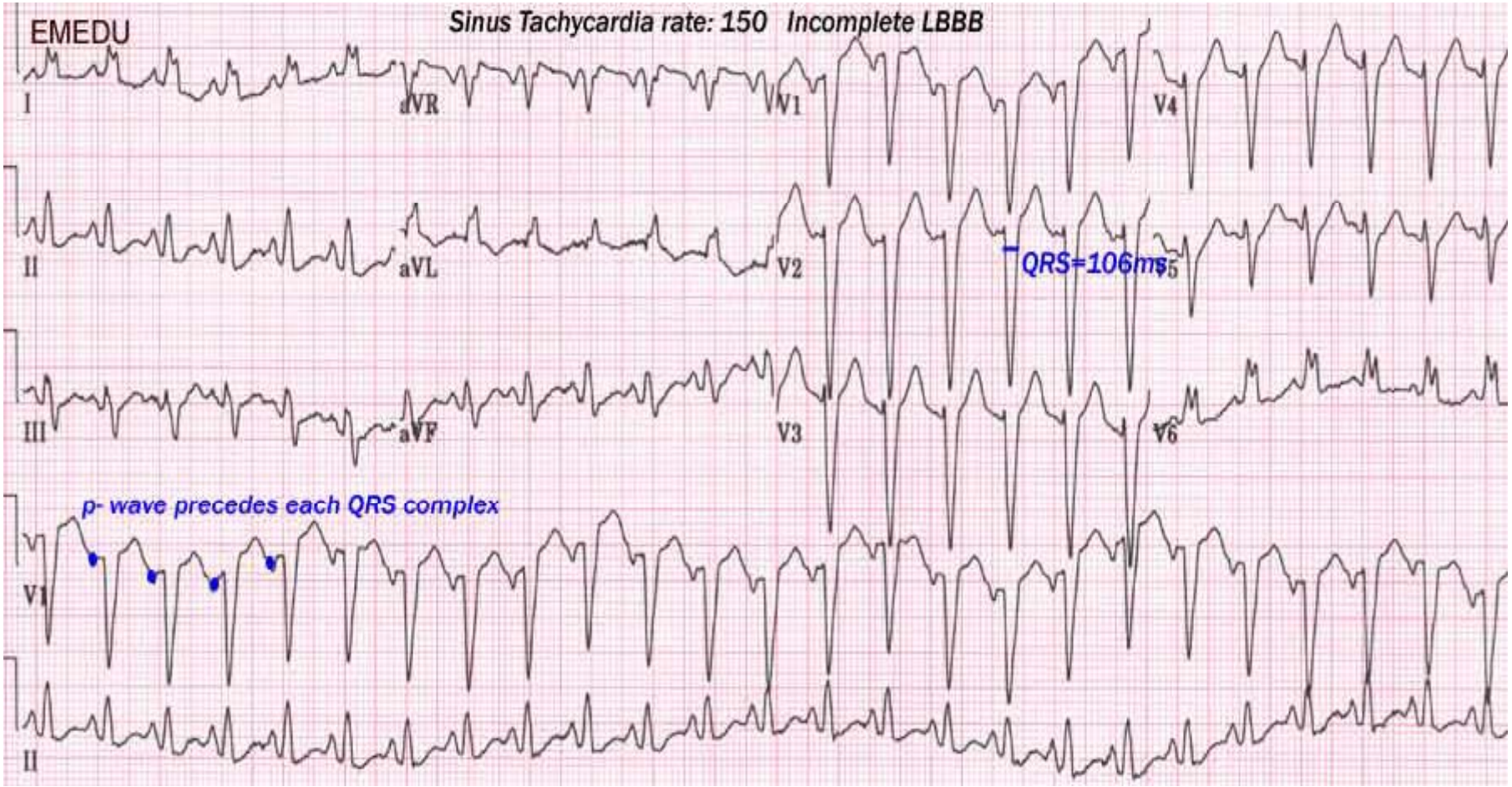

Tanınız nedir ?

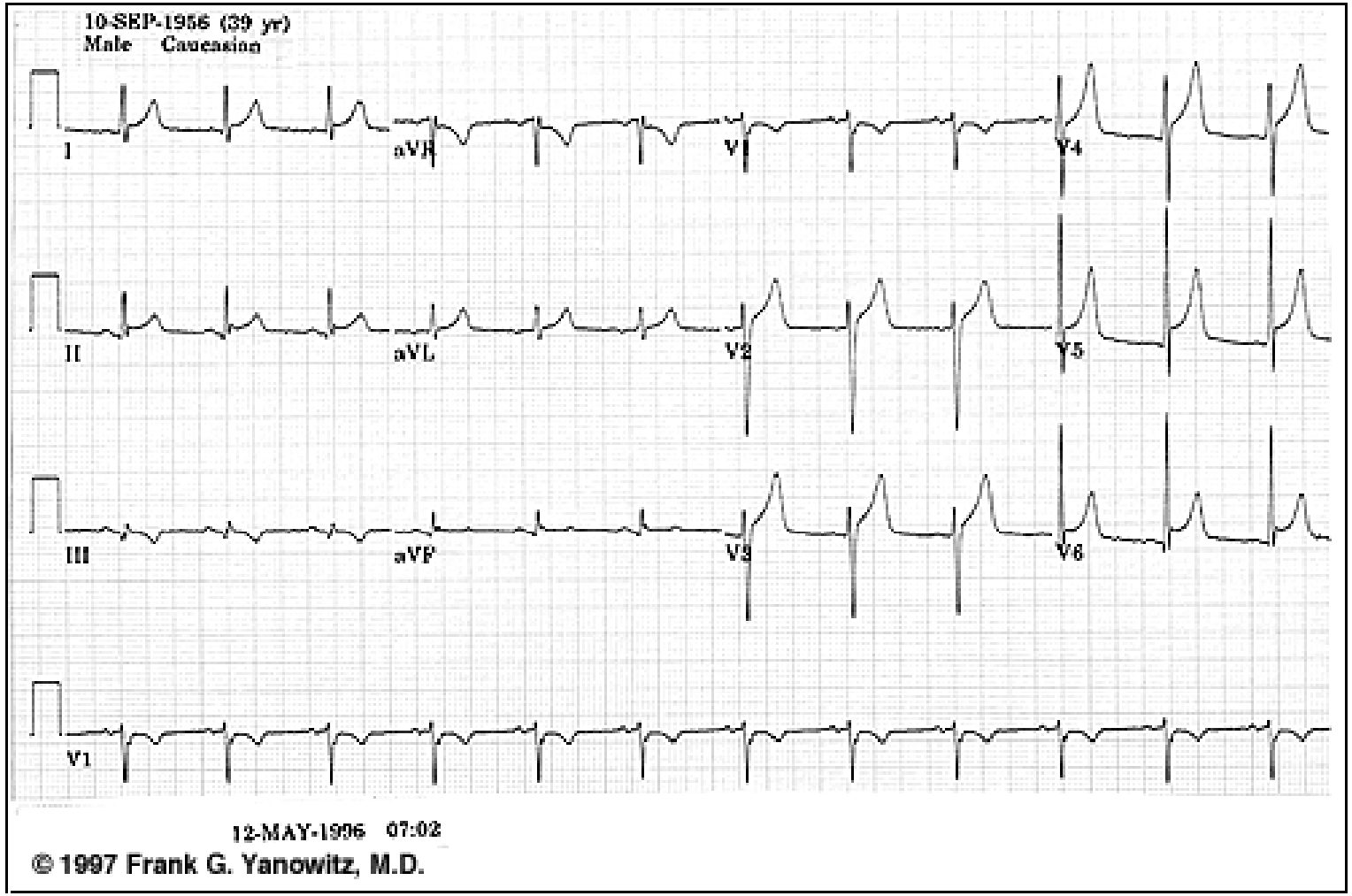

Sinüs ritmi, erken repolarizasyon

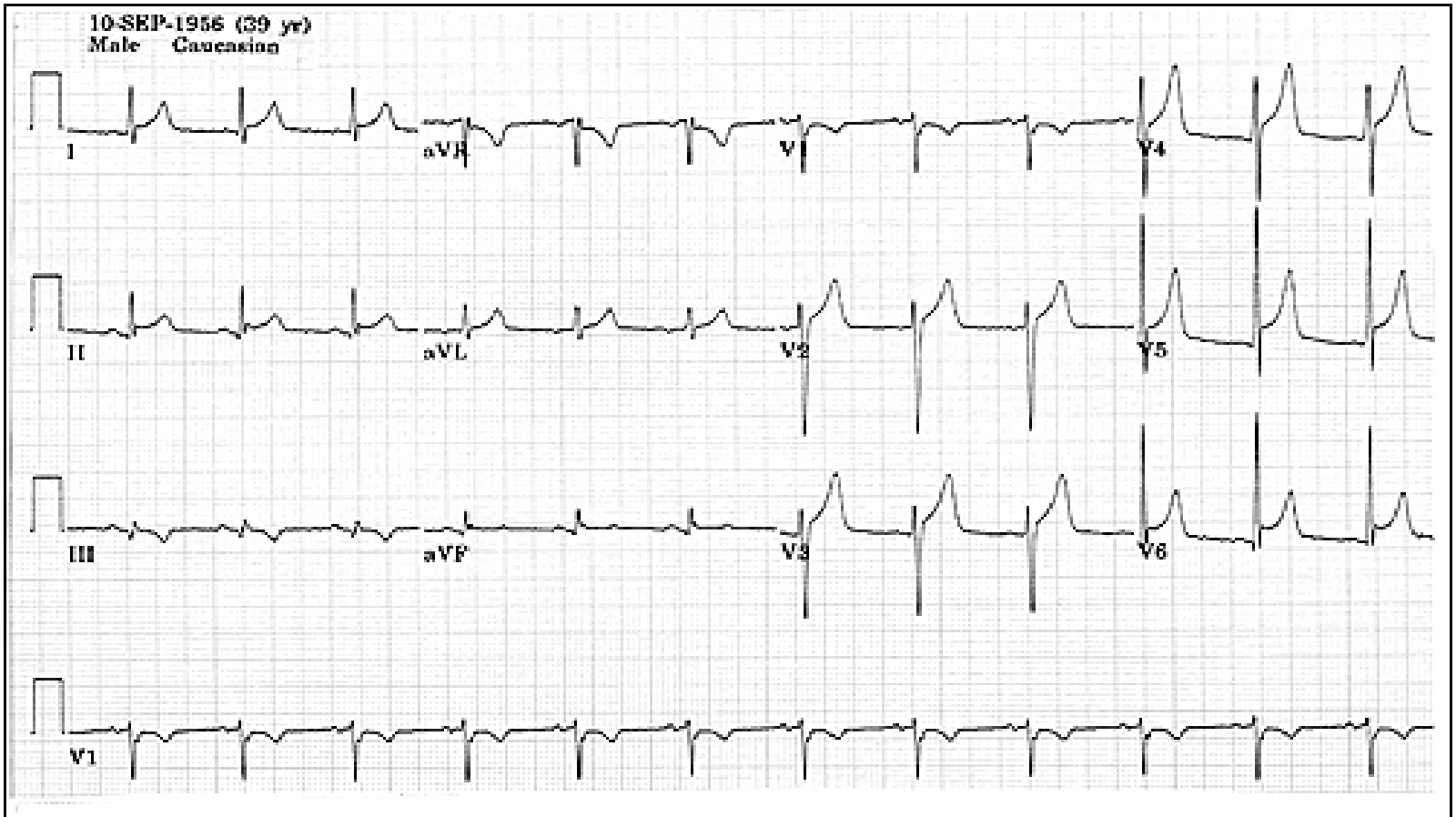

Konkav ST segment elevasyonu ve J noktası yükselmesi

Tanınız nedir ?

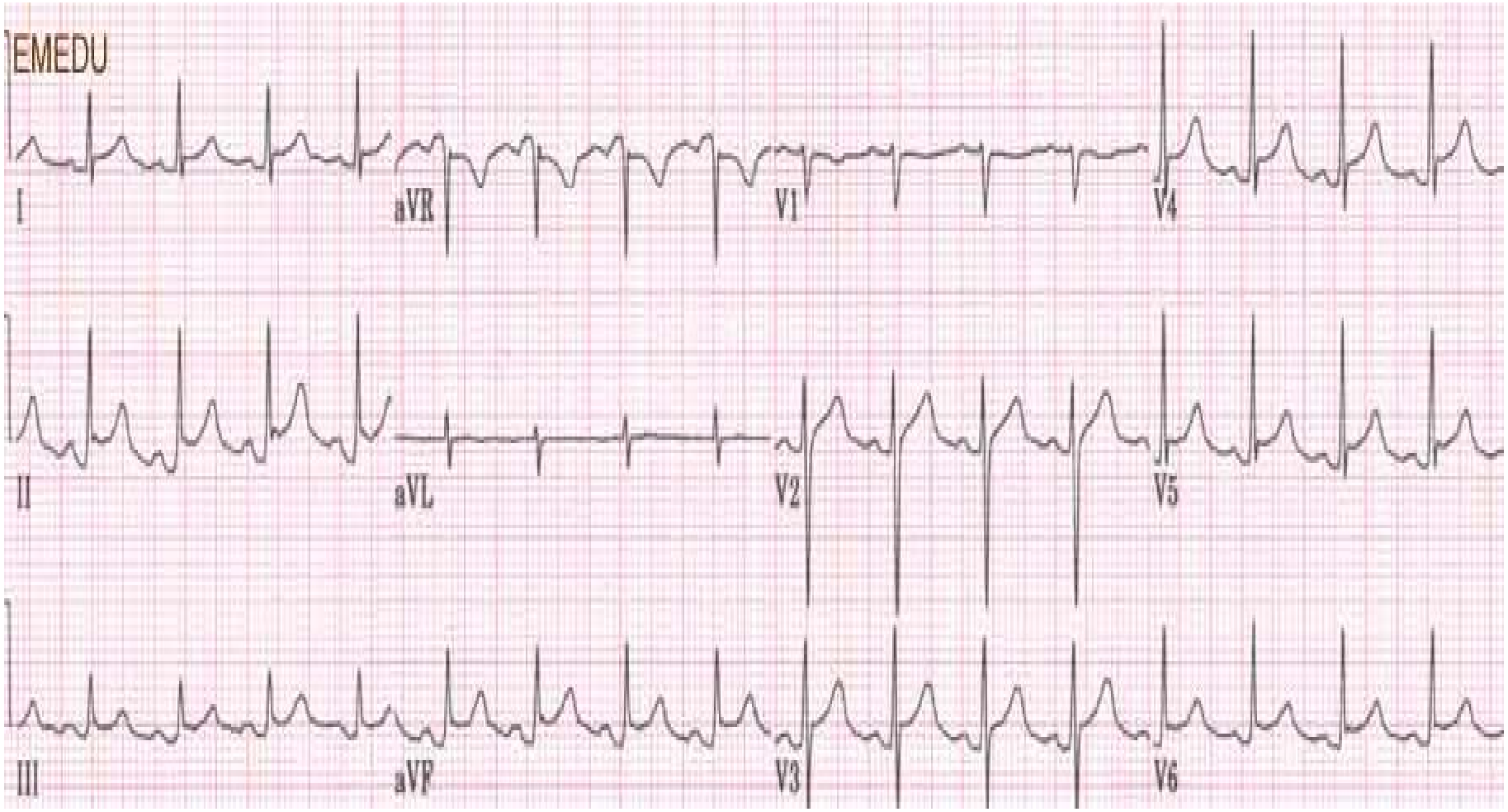

Perikardit

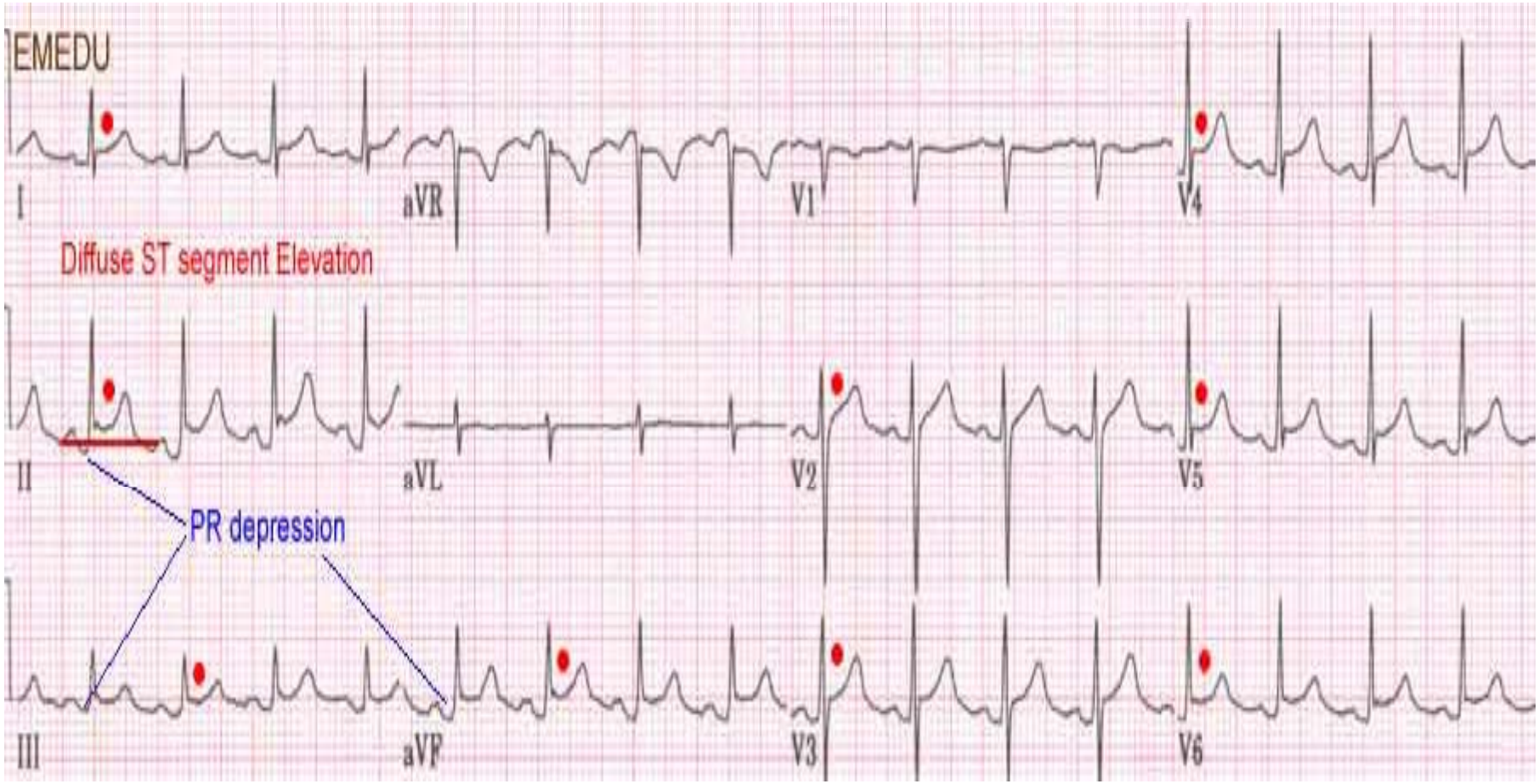
EMEDU
I
aVR
V1
V4
Diffuse ST segment Elevation
II
aVL
V2
V5
PR depression
III
aVF
V3
V6

Tanınız nedir ?

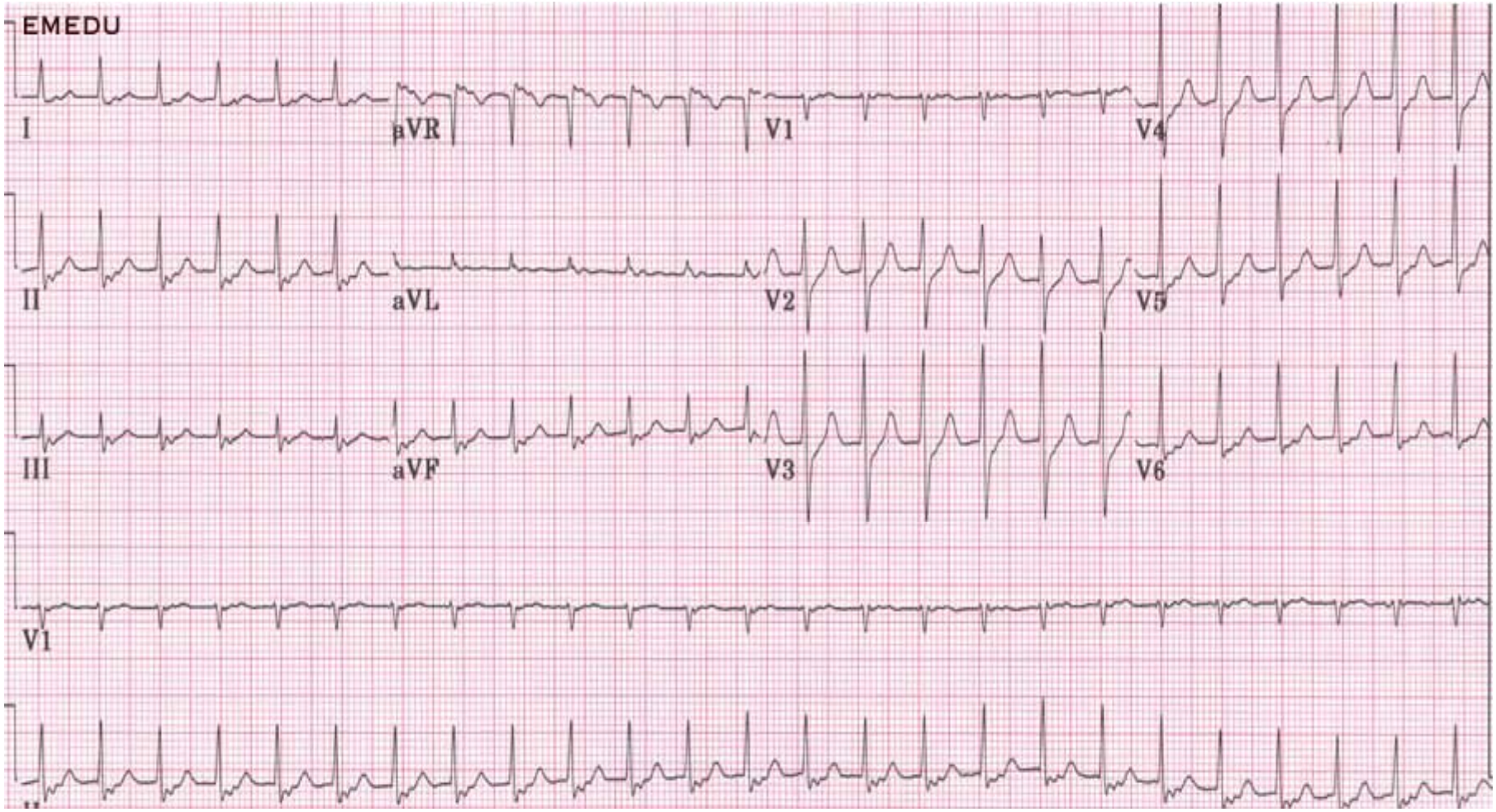

Supraventriküler Taşikardi

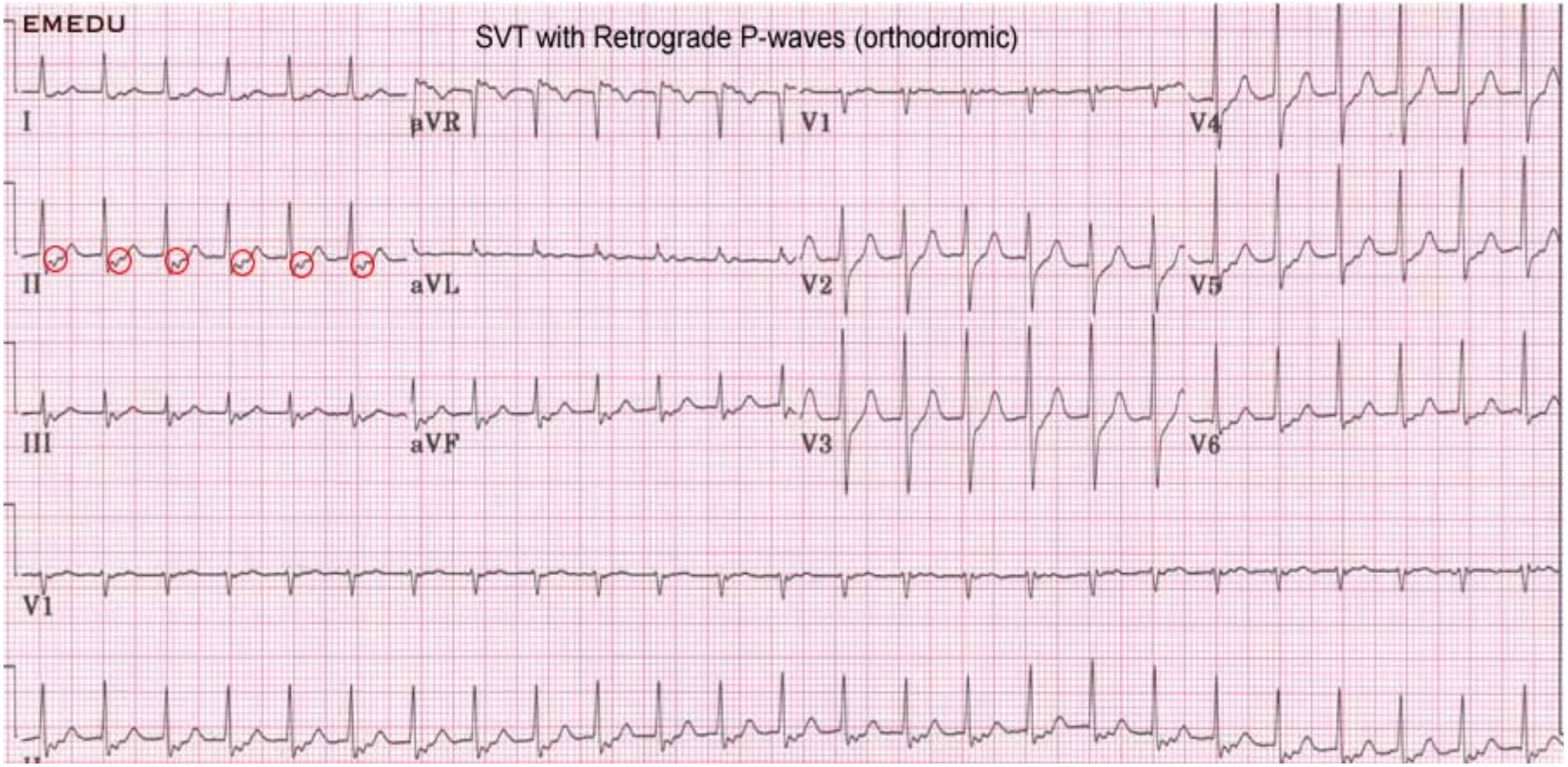

Tanınız nedir ?

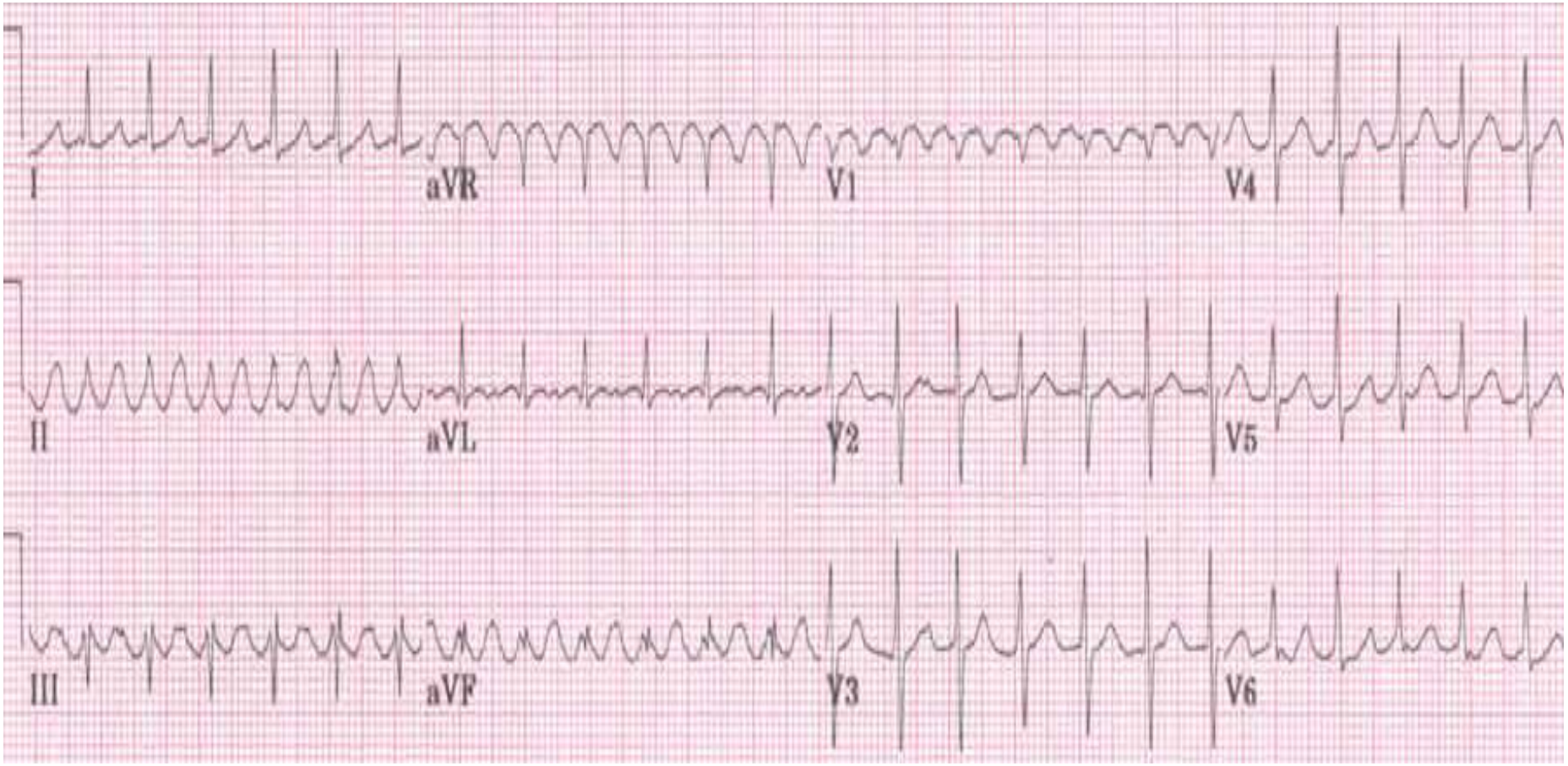

2:1 Geçişli Atriyal Flatter

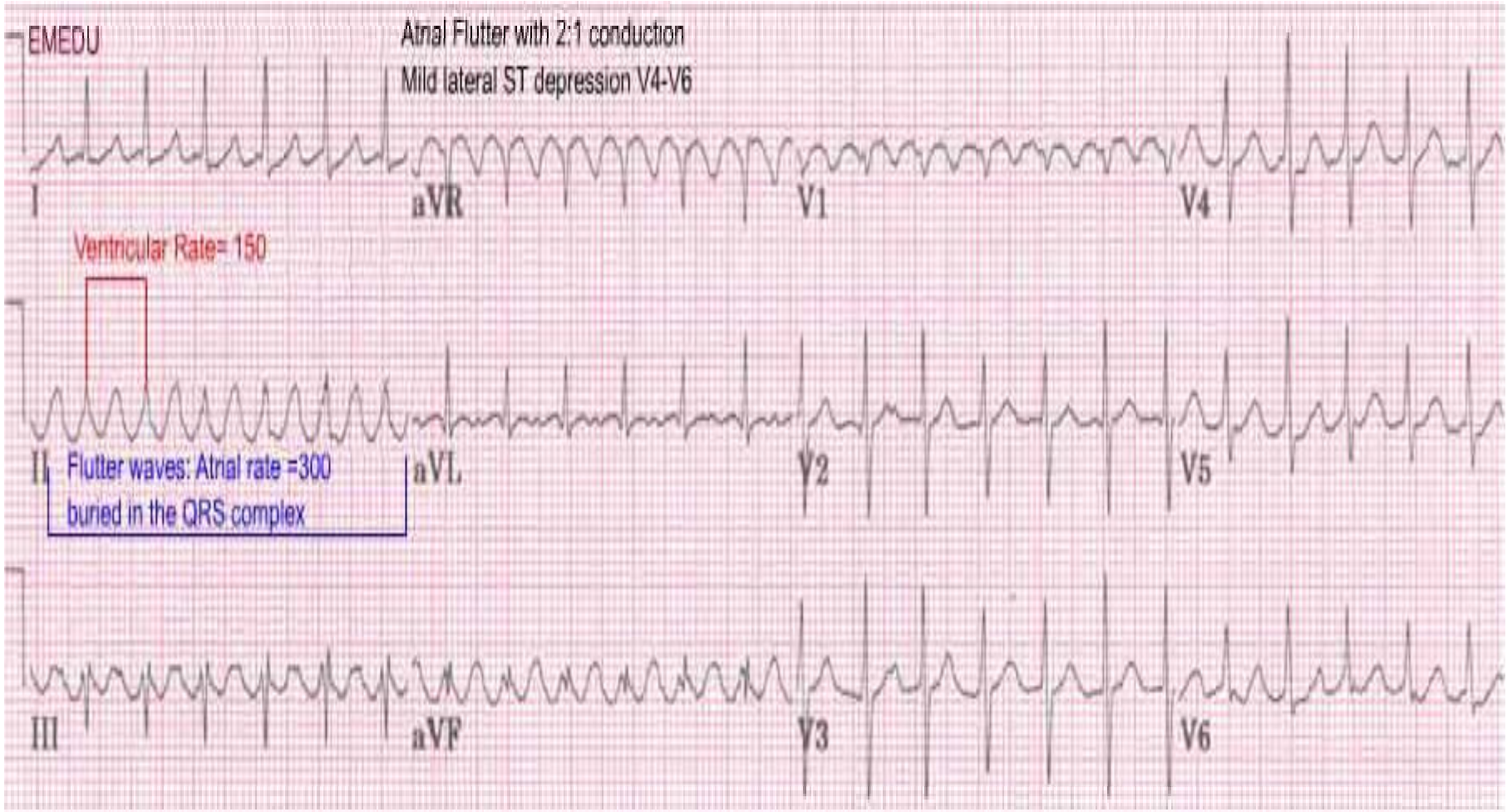

Tanınız nedir ?

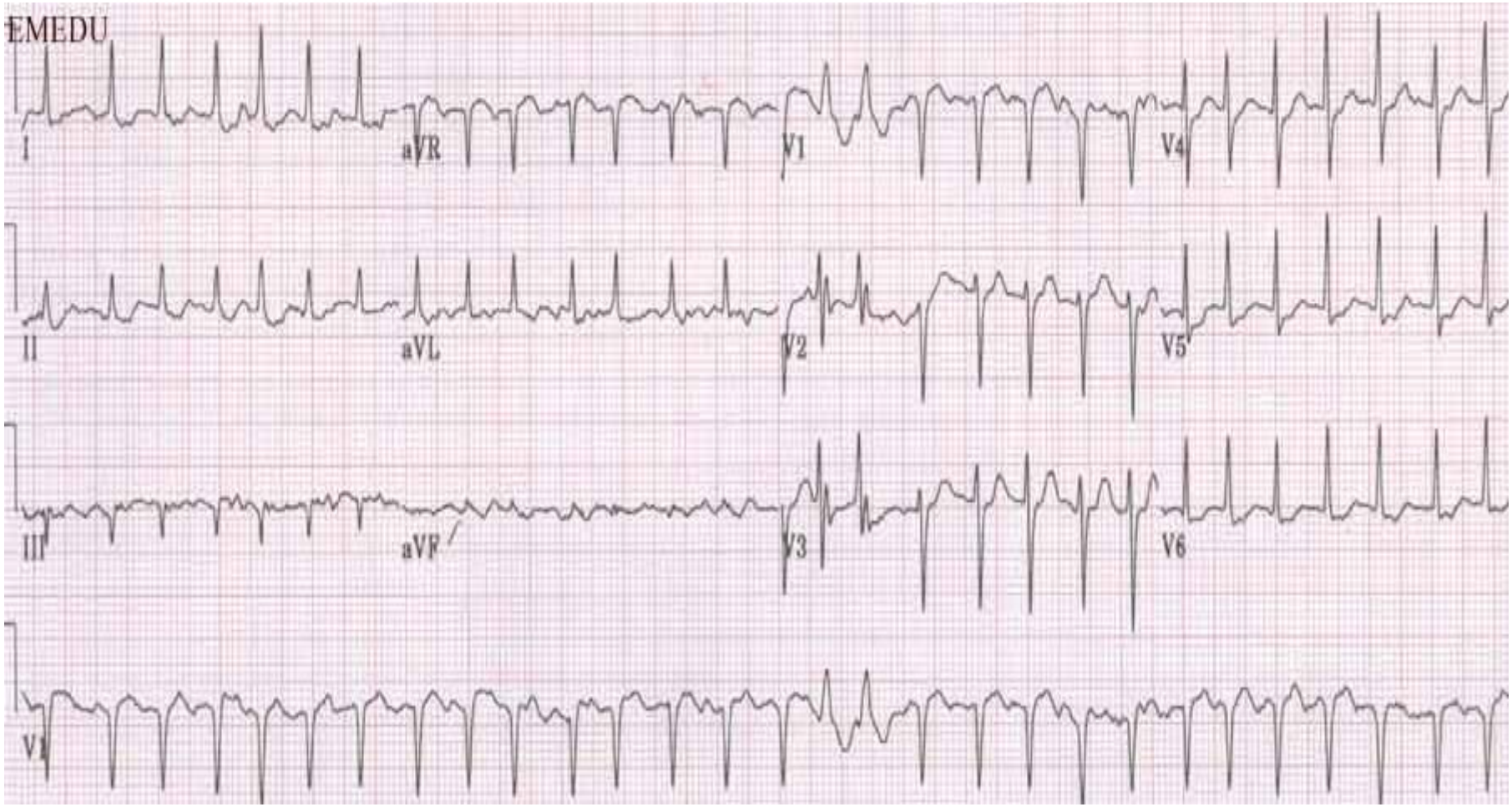

Hızlı Ventriküler yanıtlı Atriyal Fibrilasyon

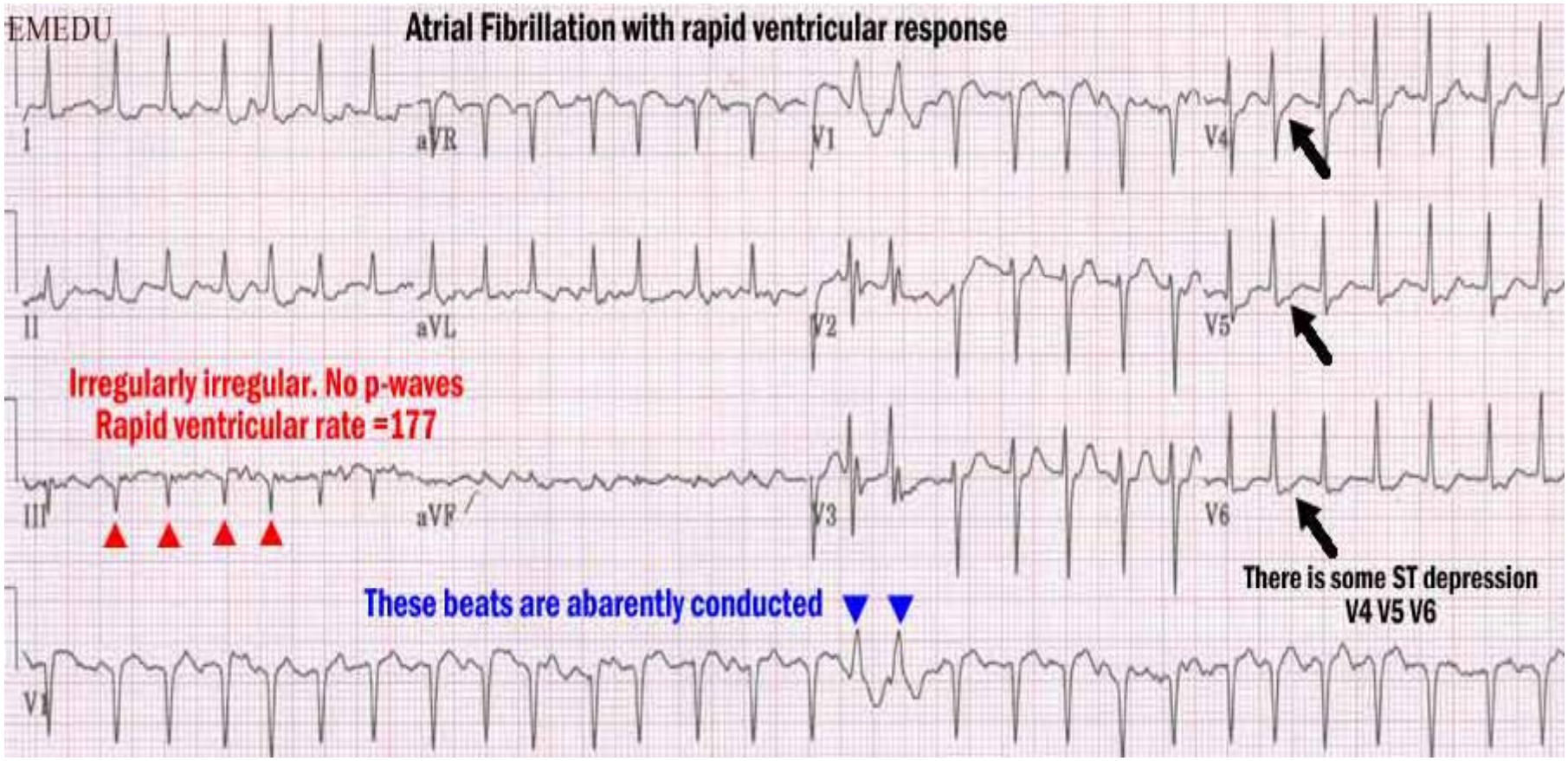

Tanınız nedir ?

Tanınız nedir ?

Normal Ventriküler Yanıtlı Atriyal fibrilasyon

Bloklu Atriyal flatter

Tanınız nedir ?

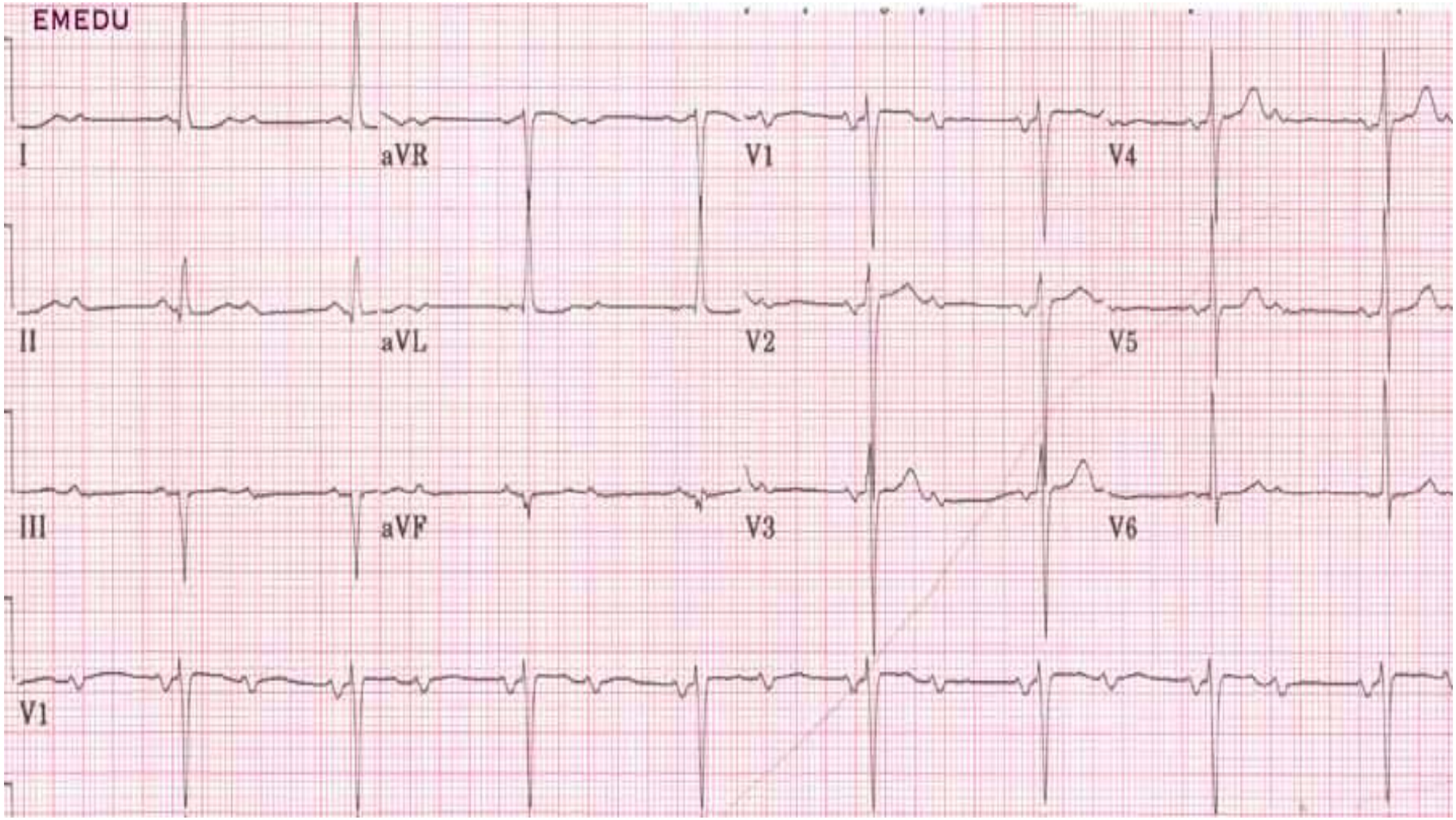

2:1 Geçişli 2° AV Blok (Möbitz Tip II)

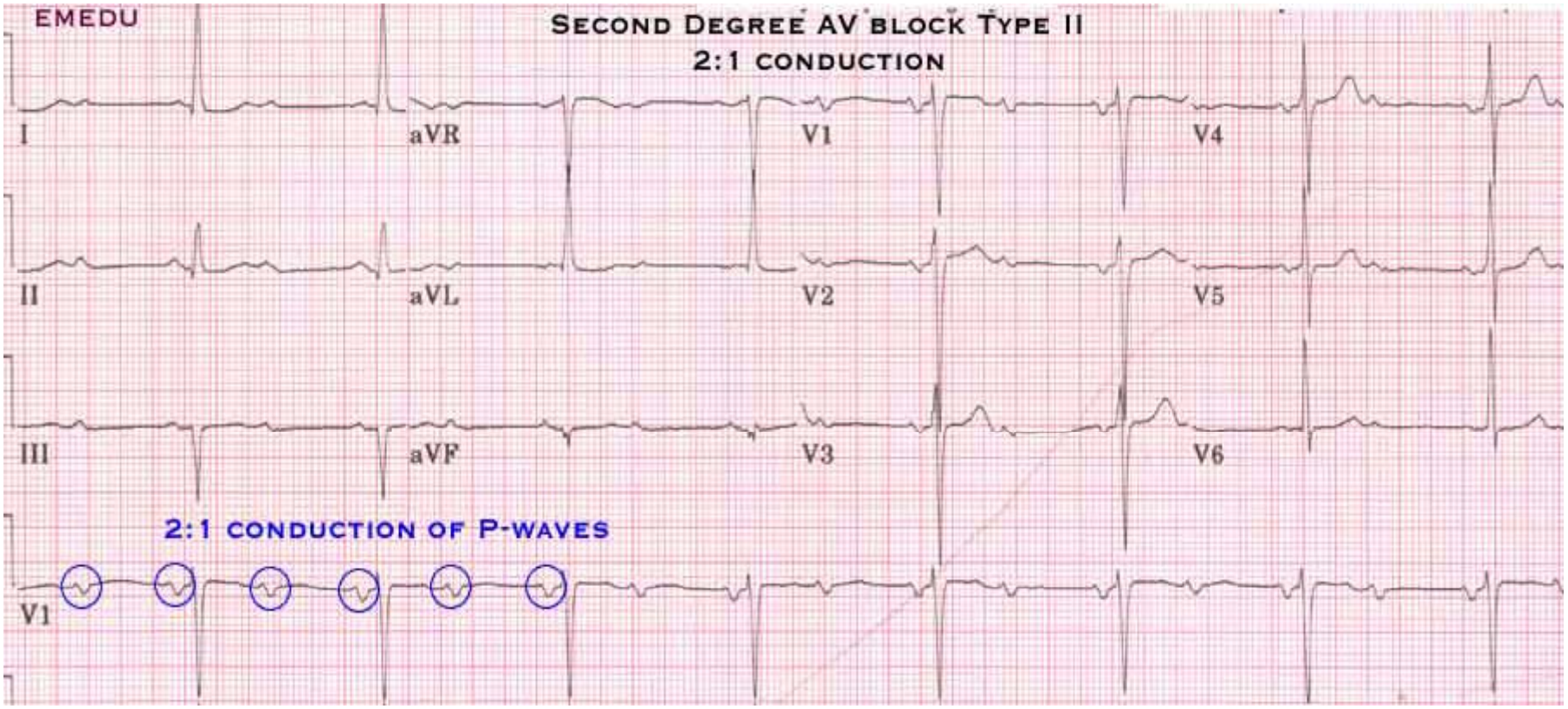

Tanınız nedir ?

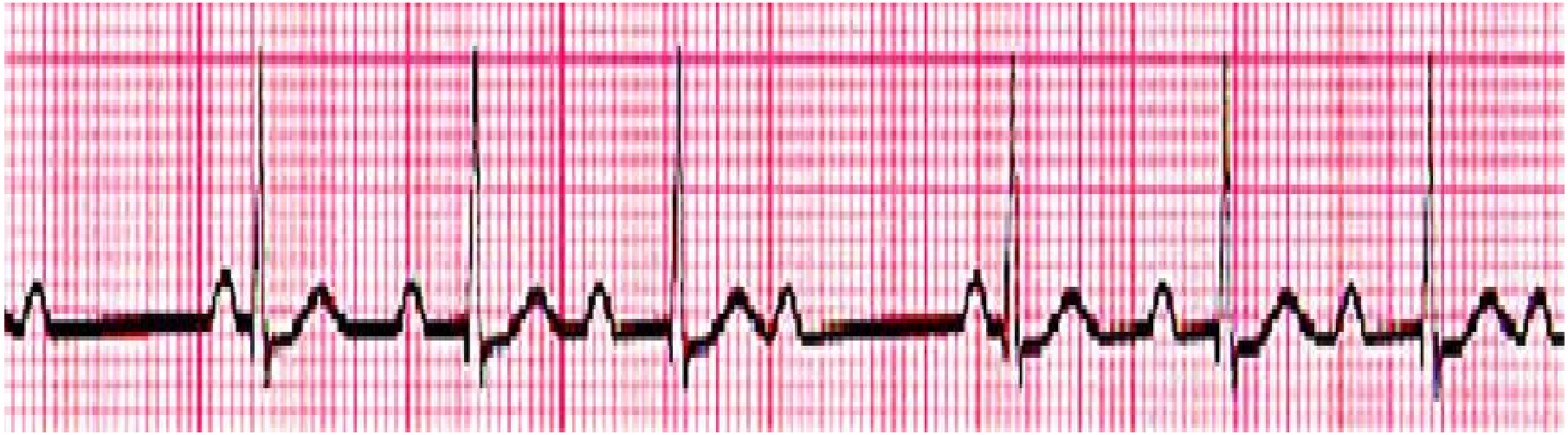

2˚ AV Blok
(Möbitz Tip I) (Wenckebach)

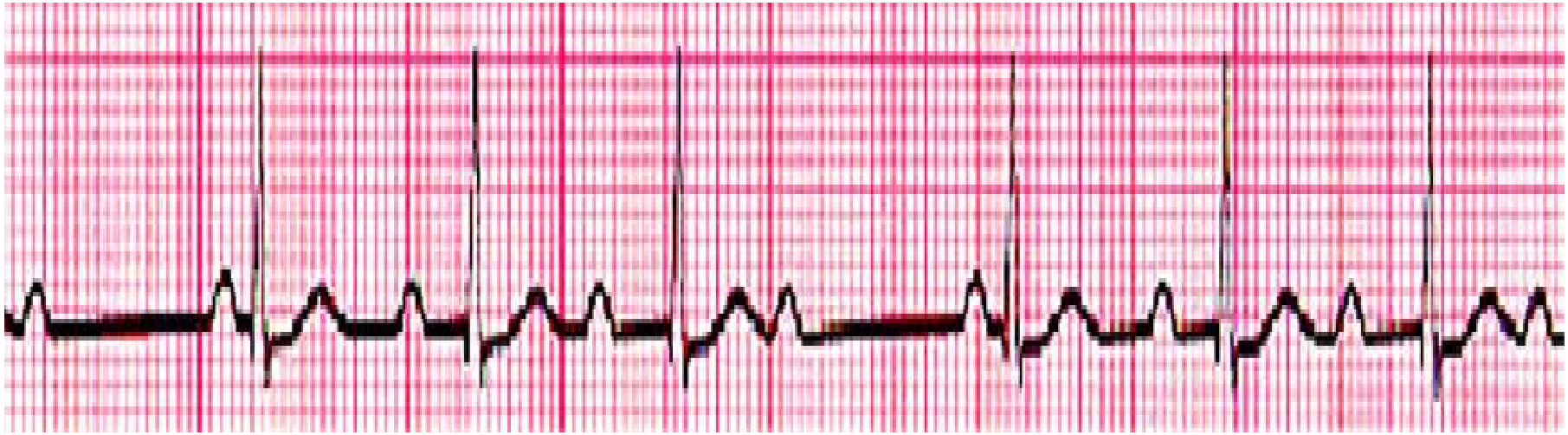

Tanınız nedir ?

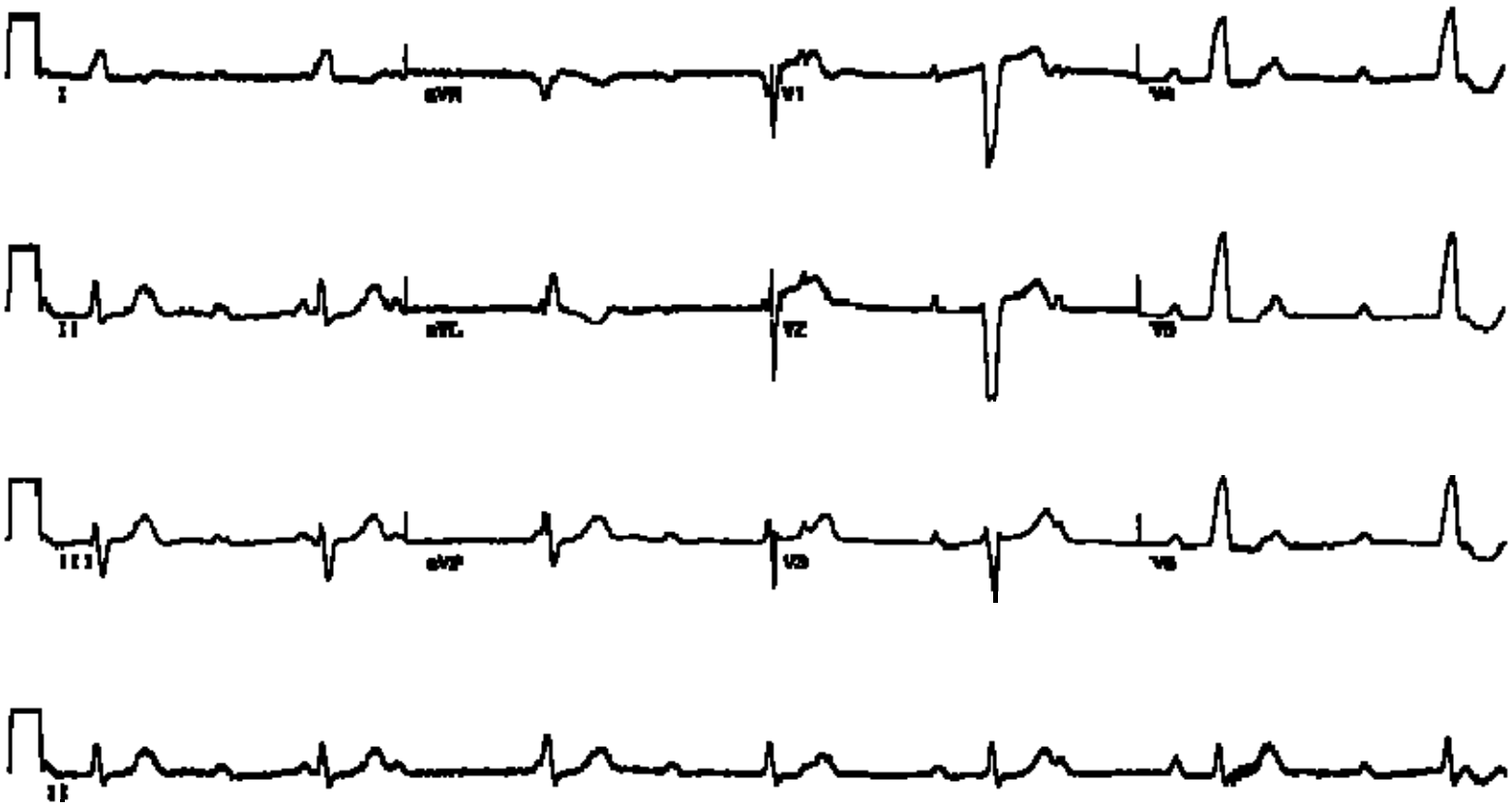

Total AV-blok

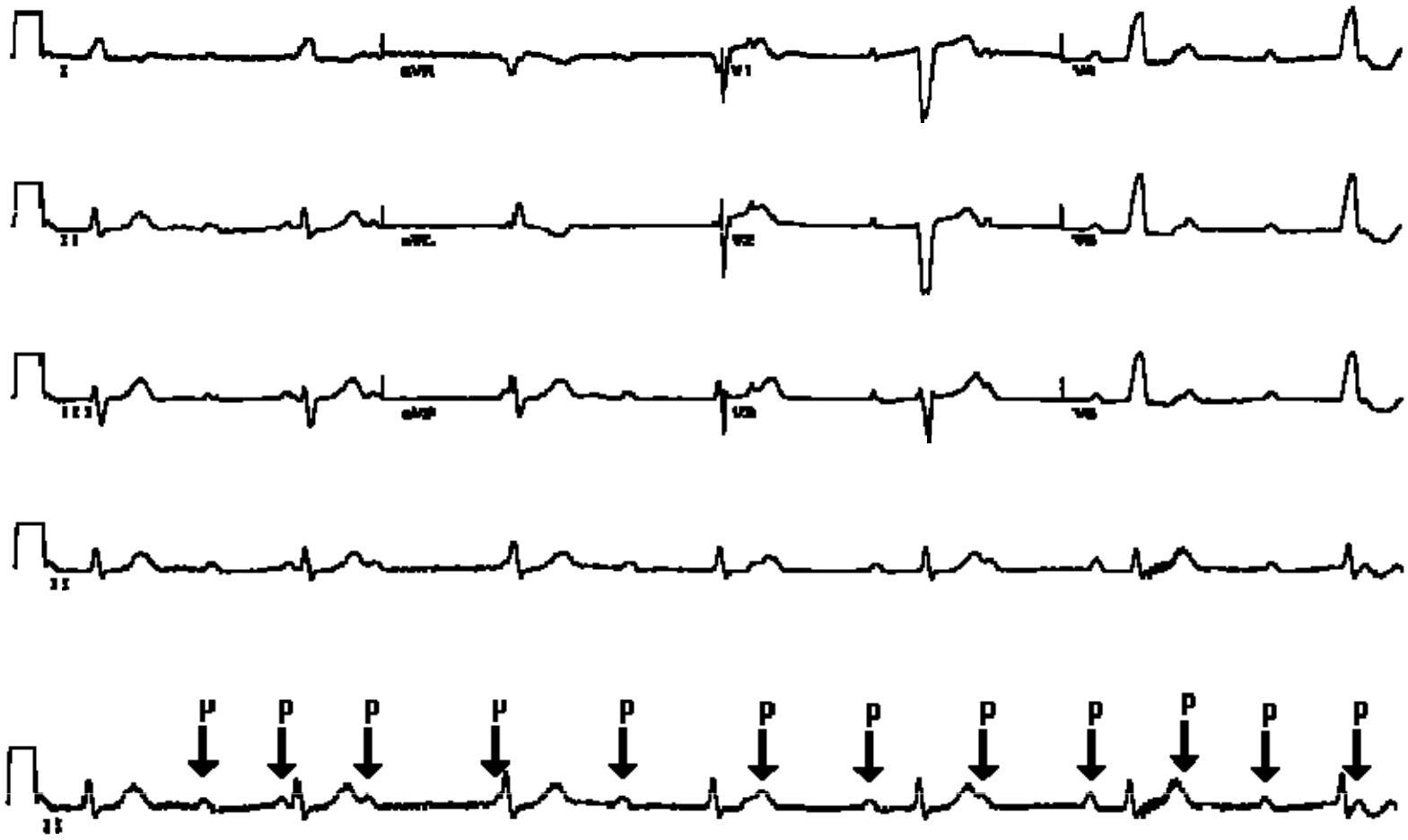

Tanınız nedir ?

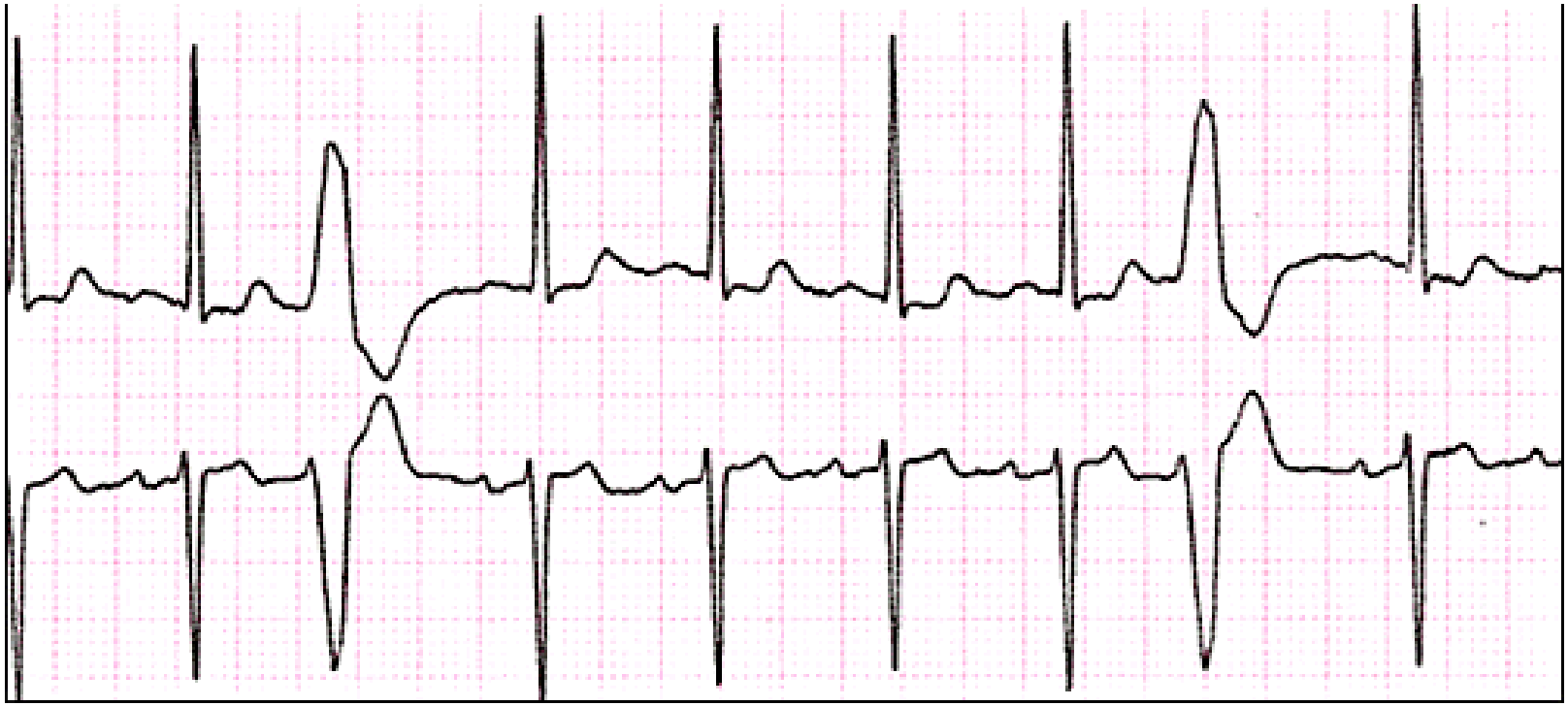

Unifokal Ventriküler erken vurular

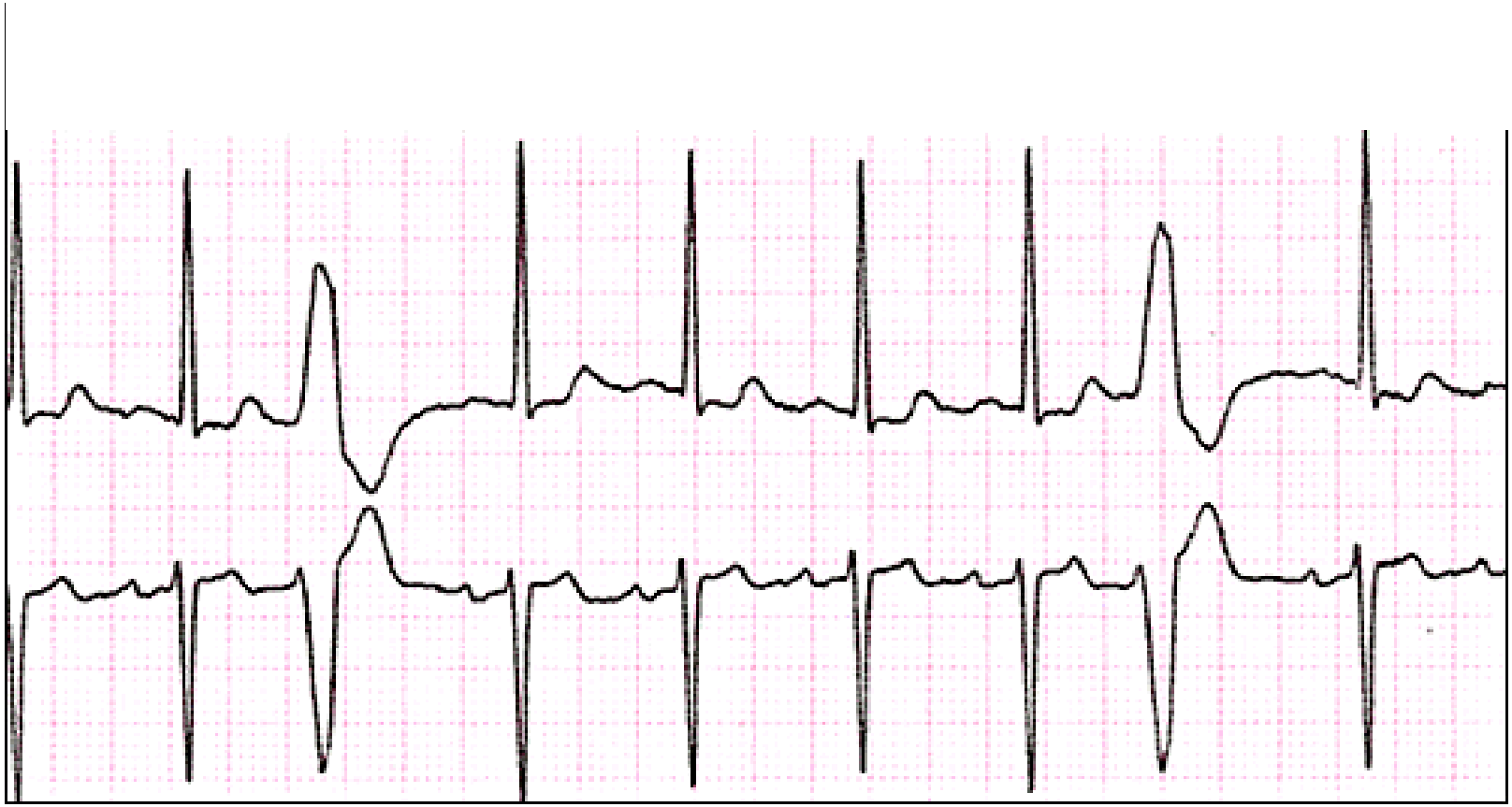

Tanınız nedir ?

Ventriküler couplet

Tanınız nedir ?

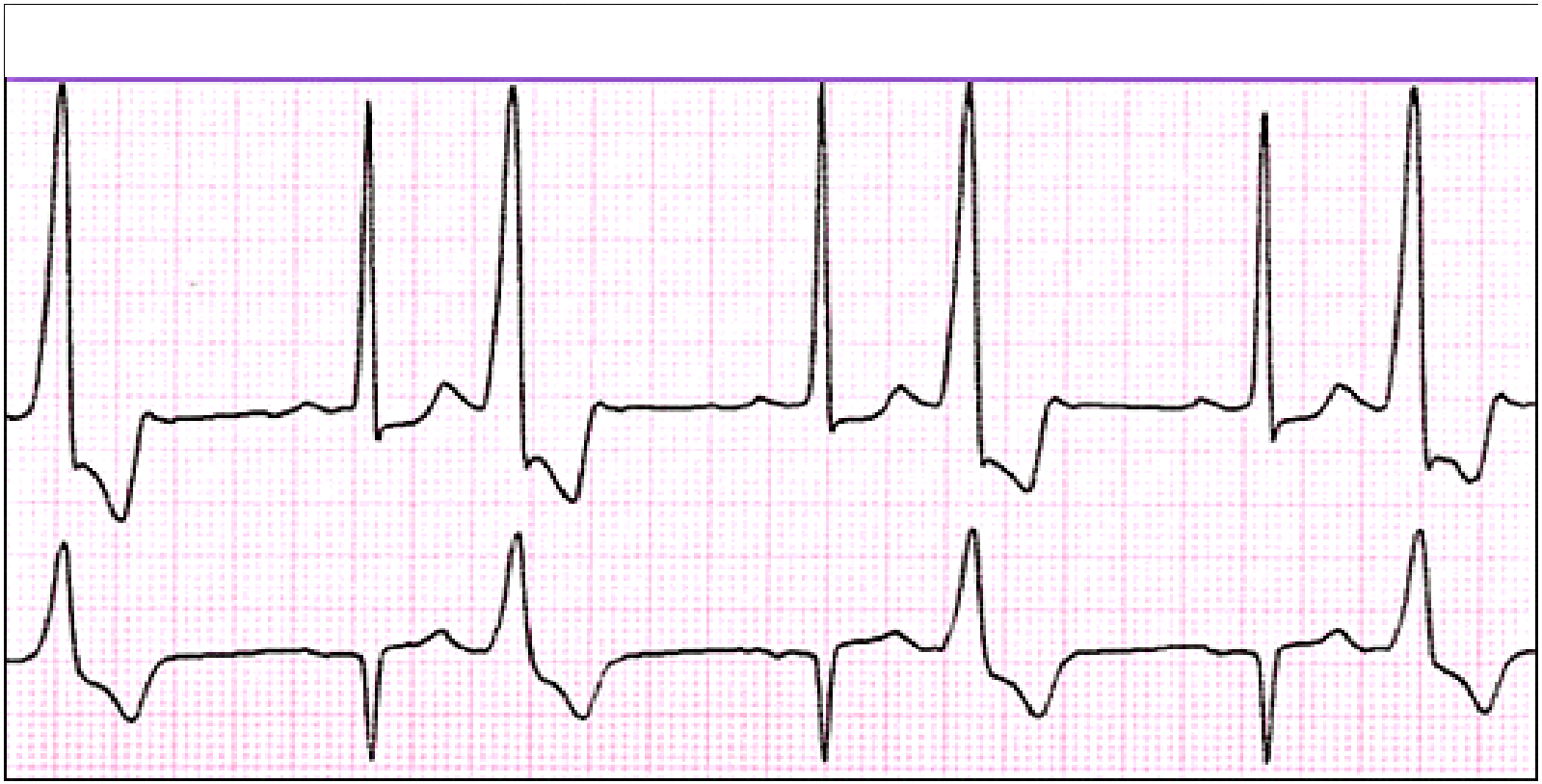

Bigemine Ventriküler erken vurular

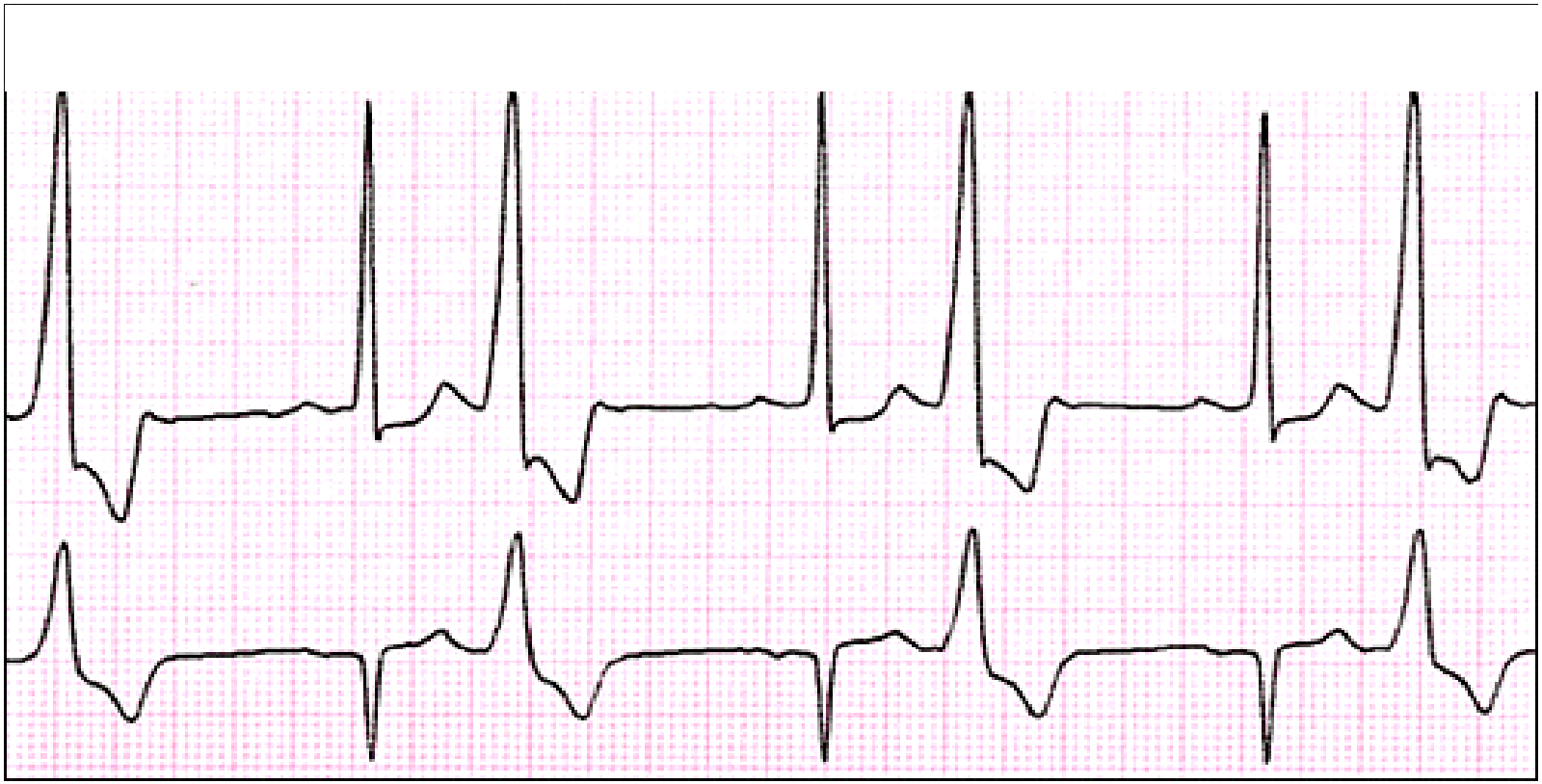

Tanınız nedir ?

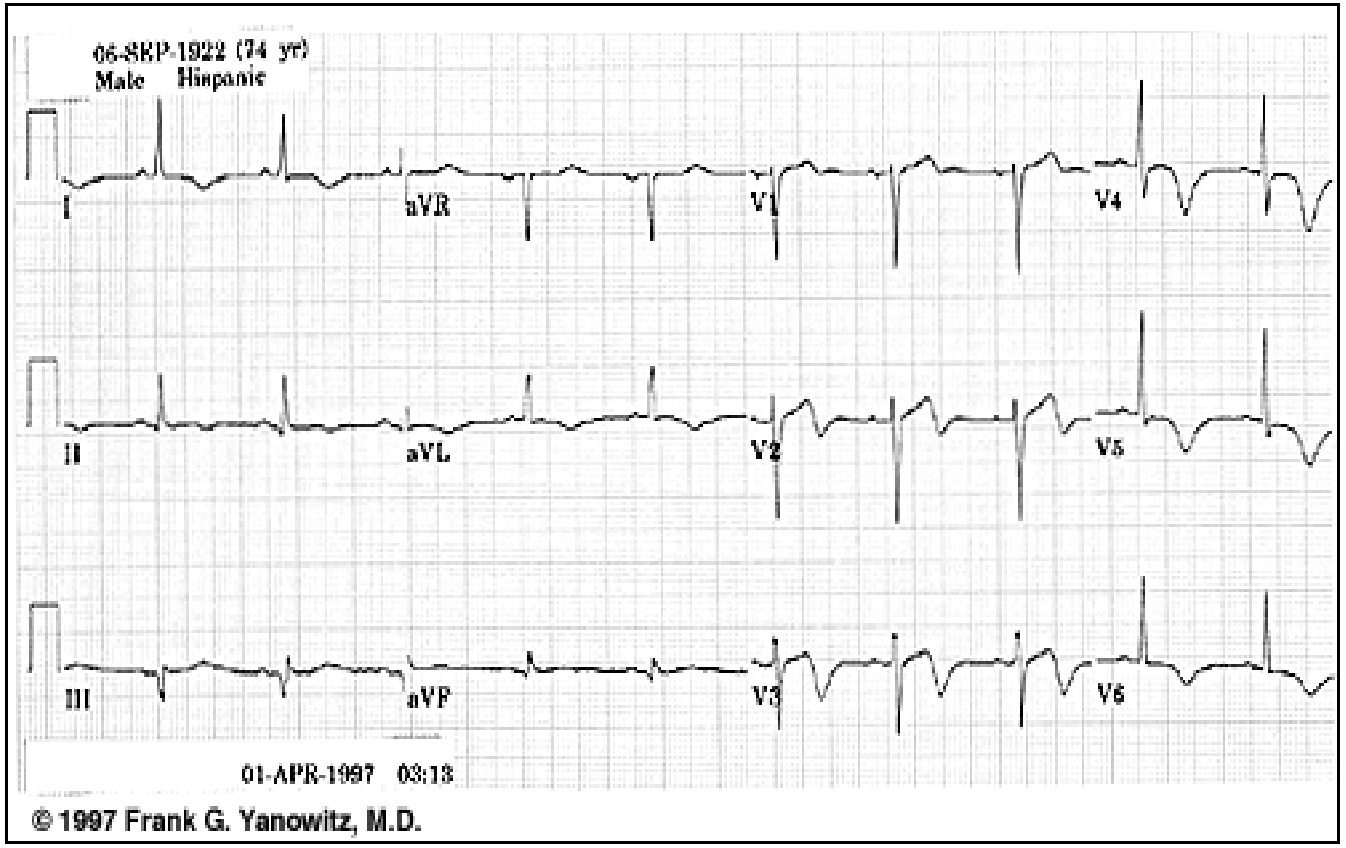

İskemi ile uyumlu T dalgası değişiklikleri

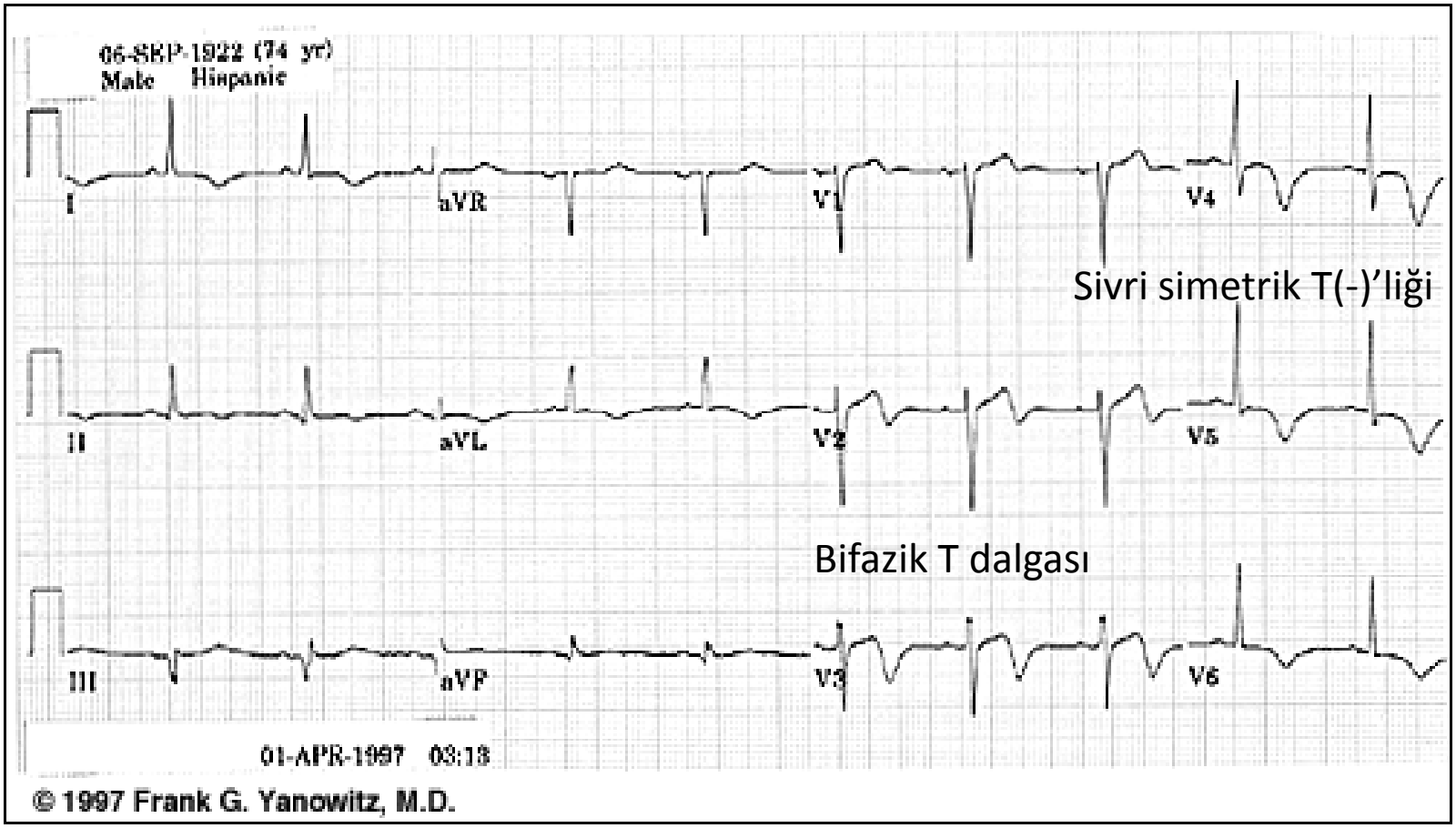

Tanınız Nedir ?

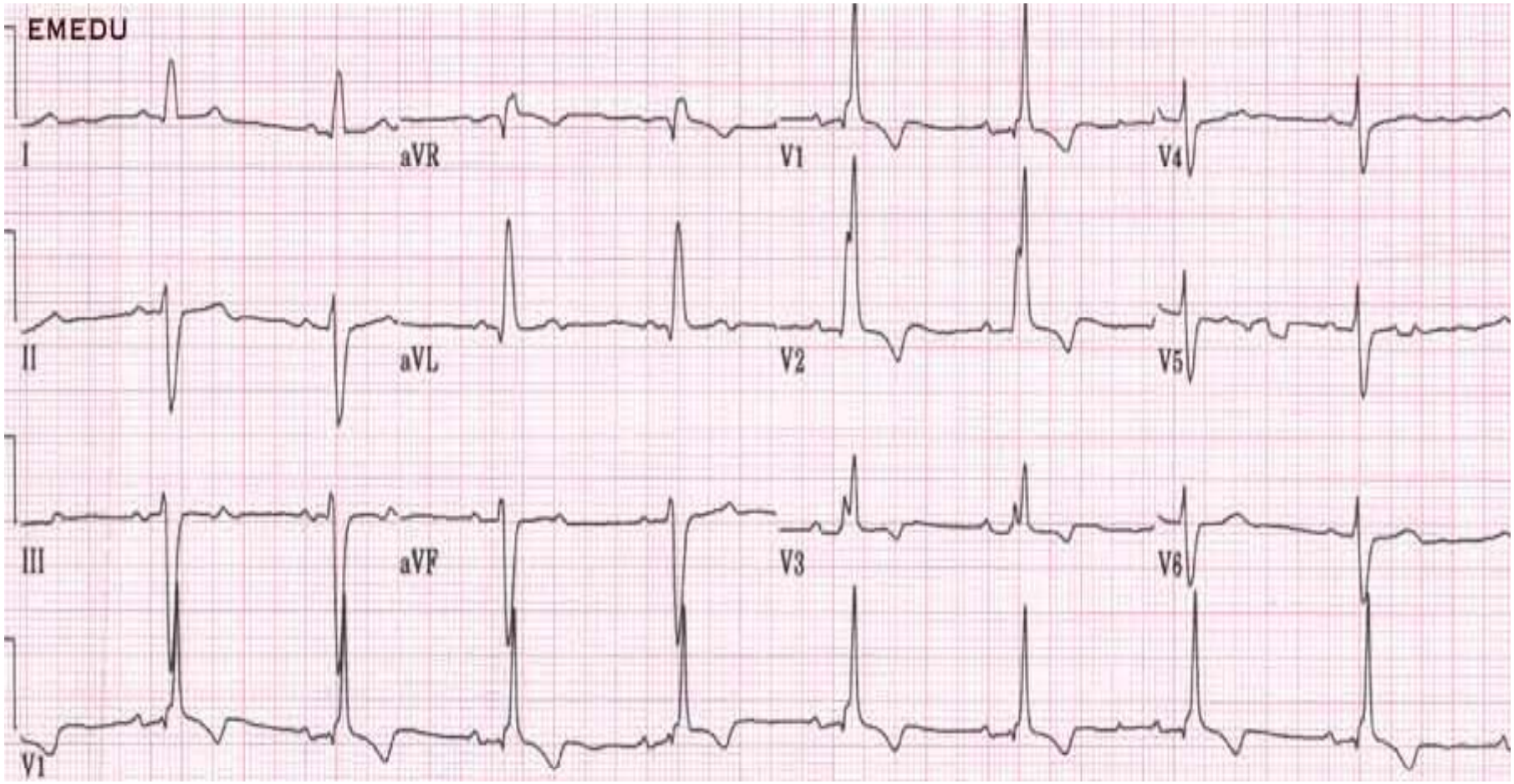

Sağ Dal Bloğu

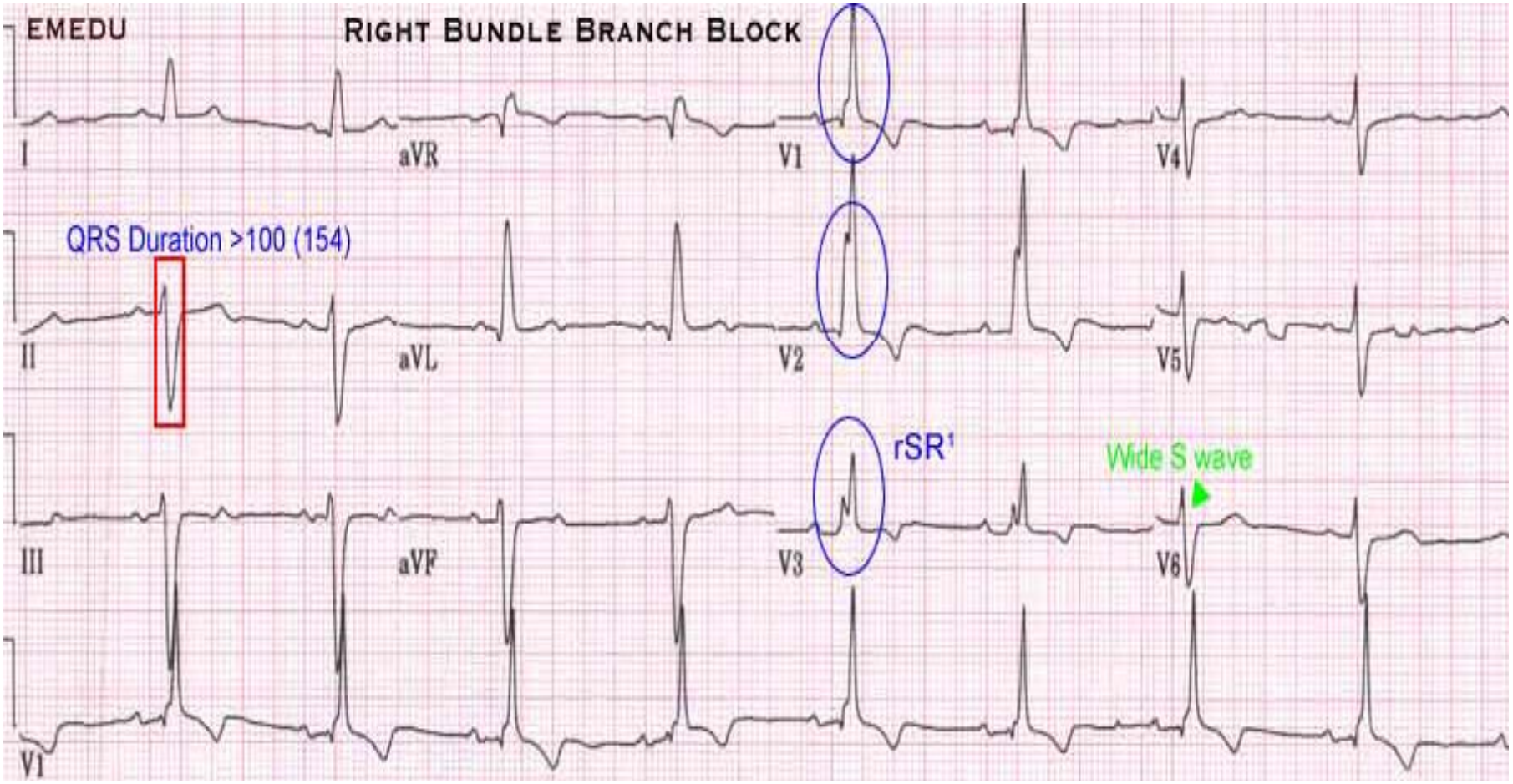

Tanınız nedir ?

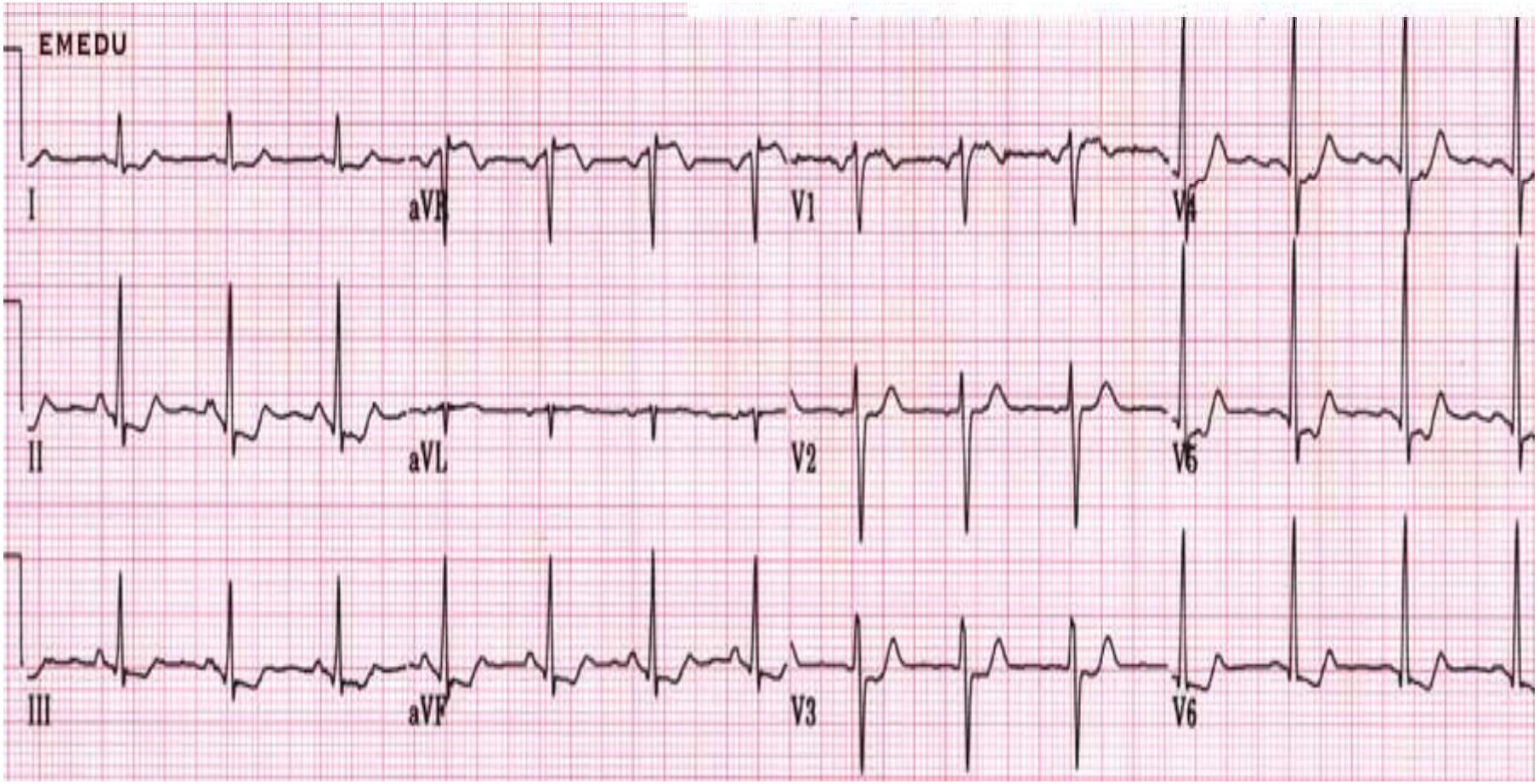

İskemi bulguları

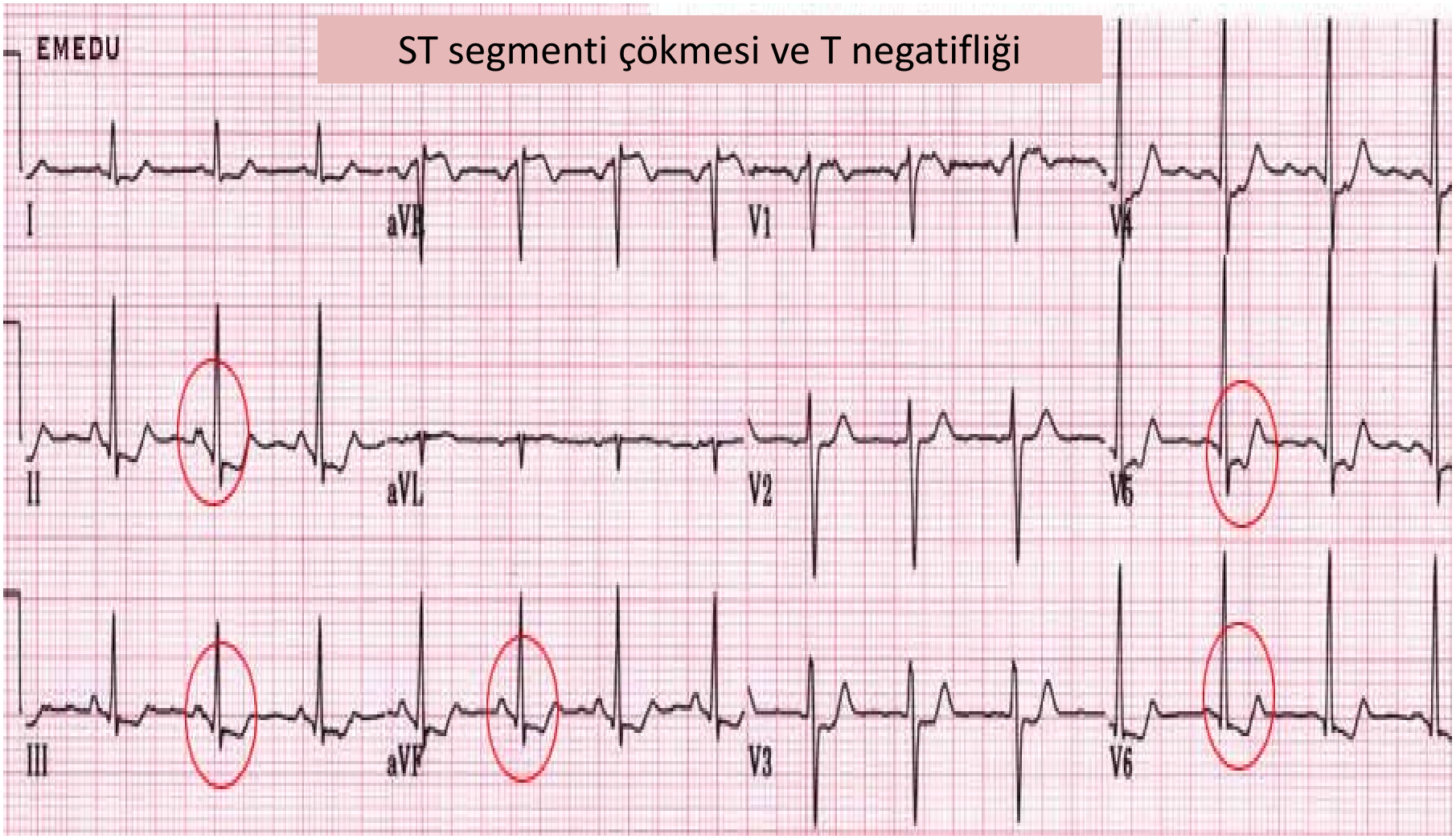

Tanınız nedir ?

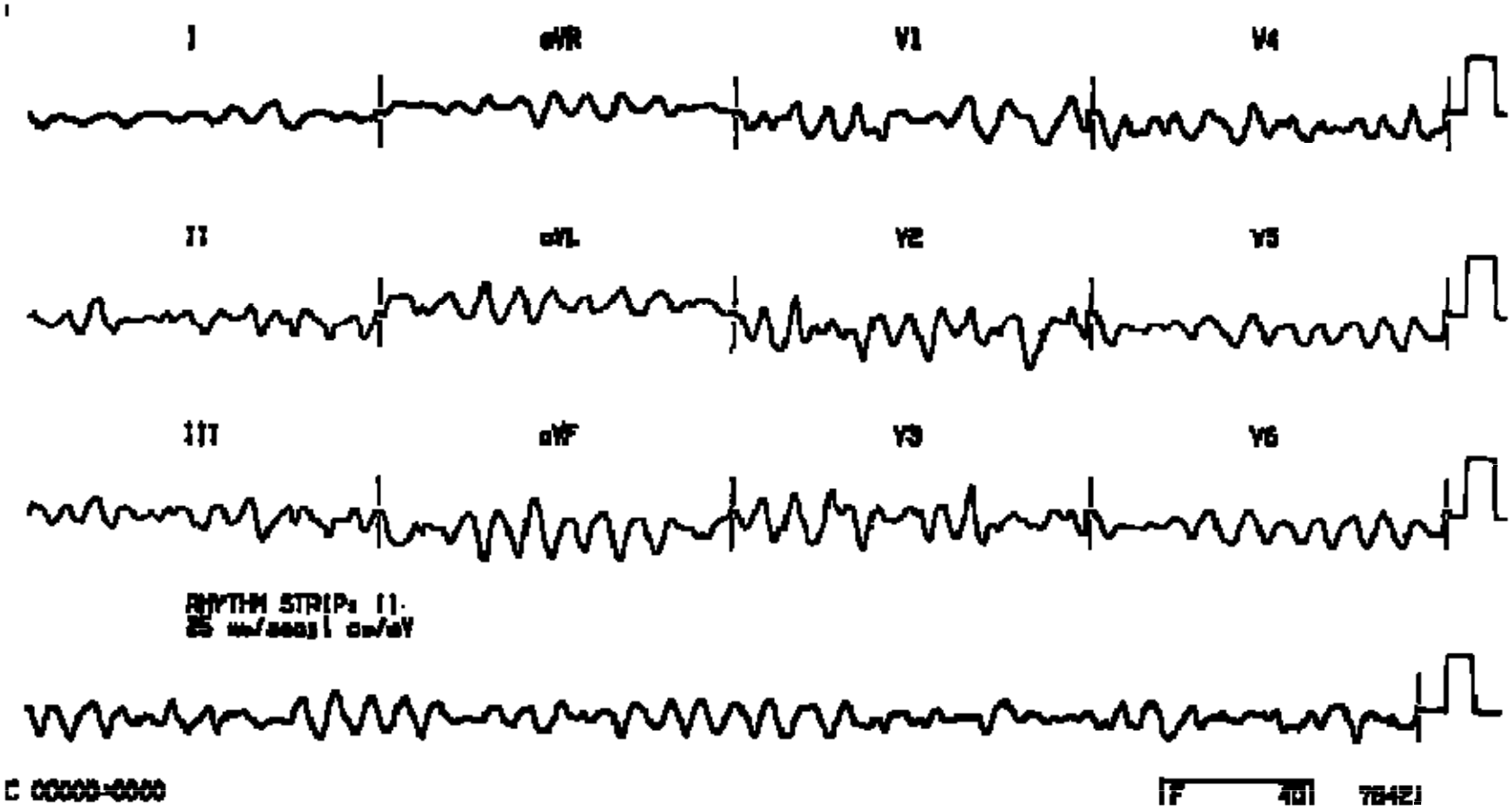

Ventriküler fibrilasyon

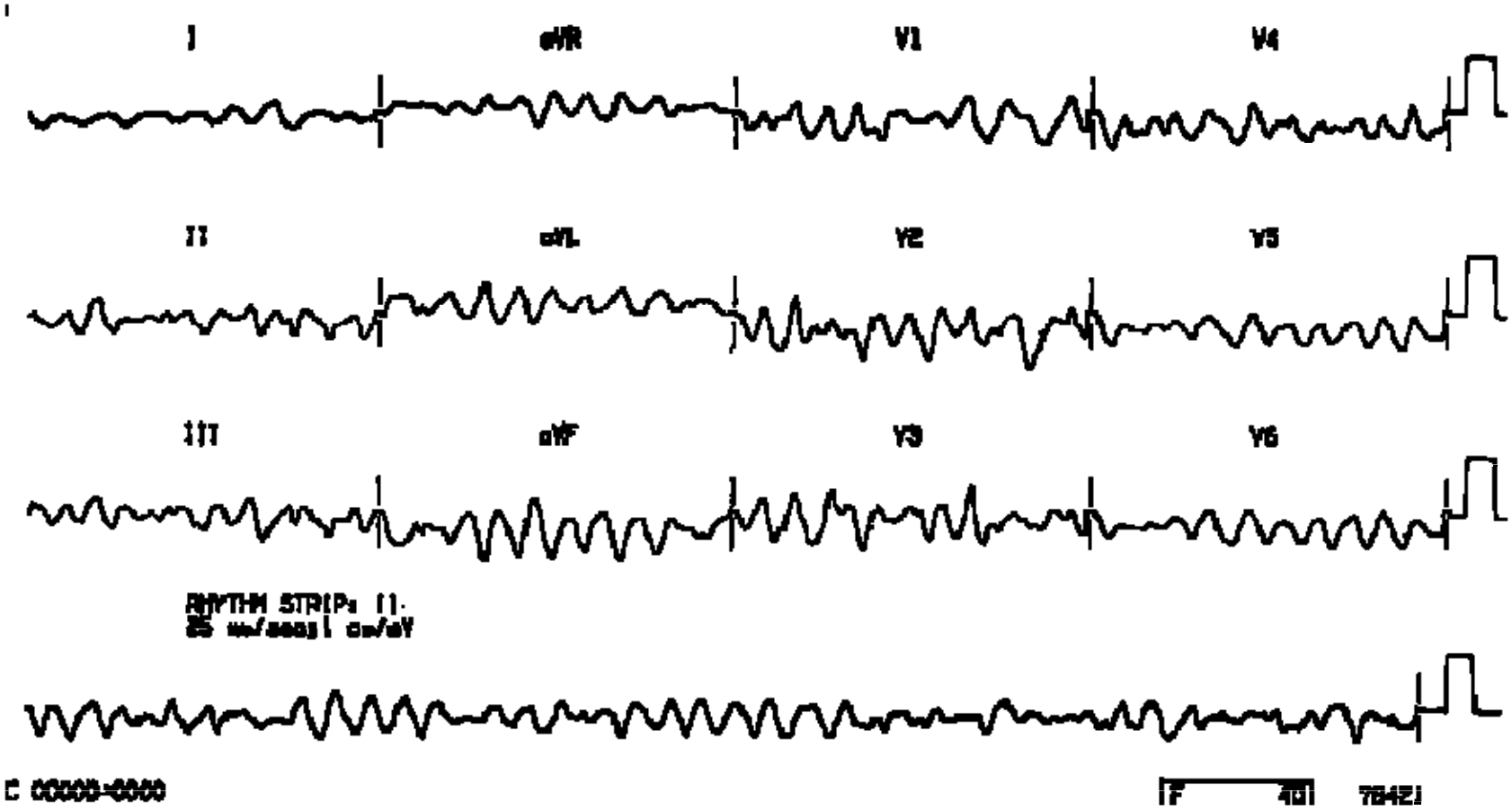

Tanınız nedir ?

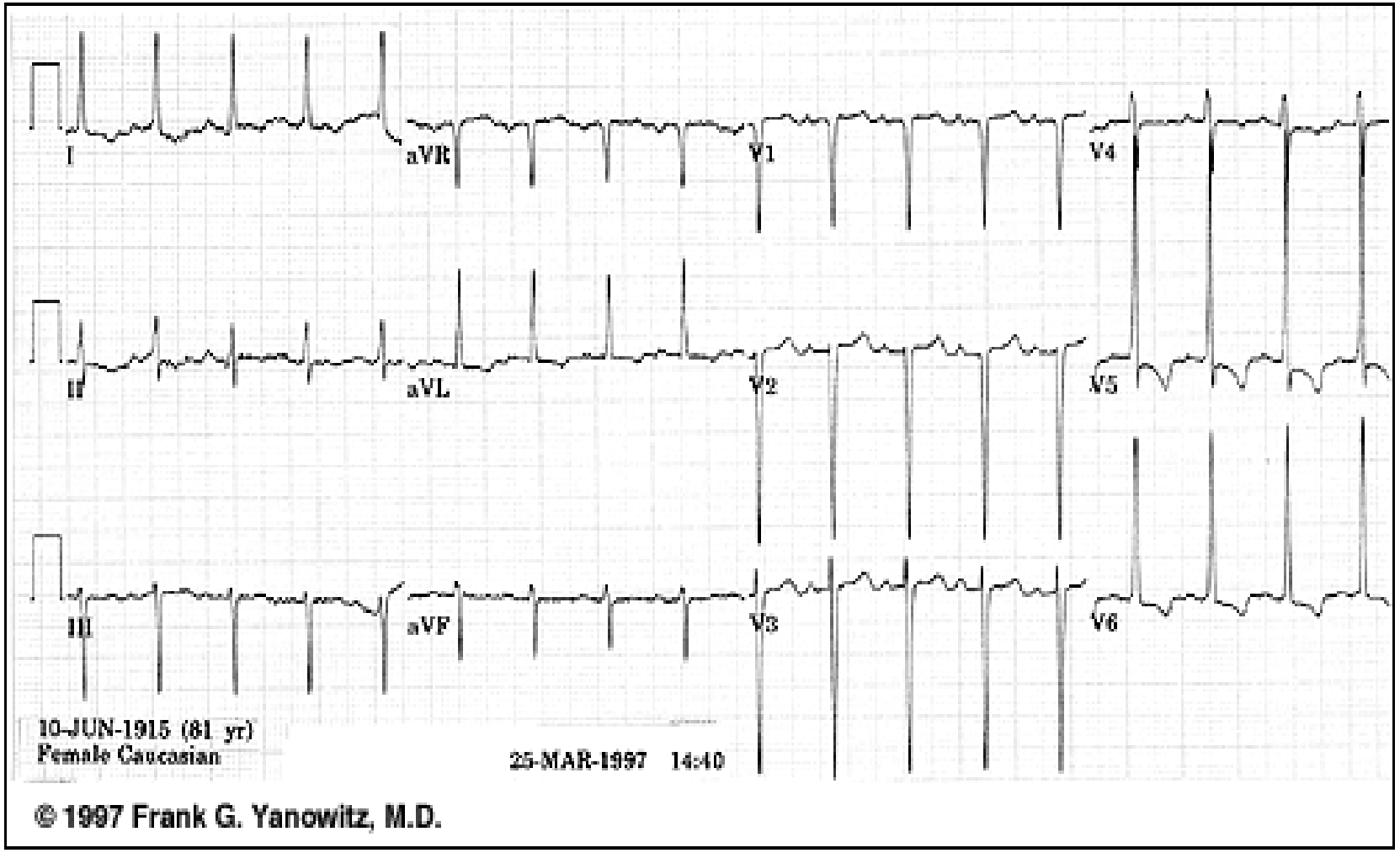

Sol ventrikül hipertrofisi ve yüklenme bulguları

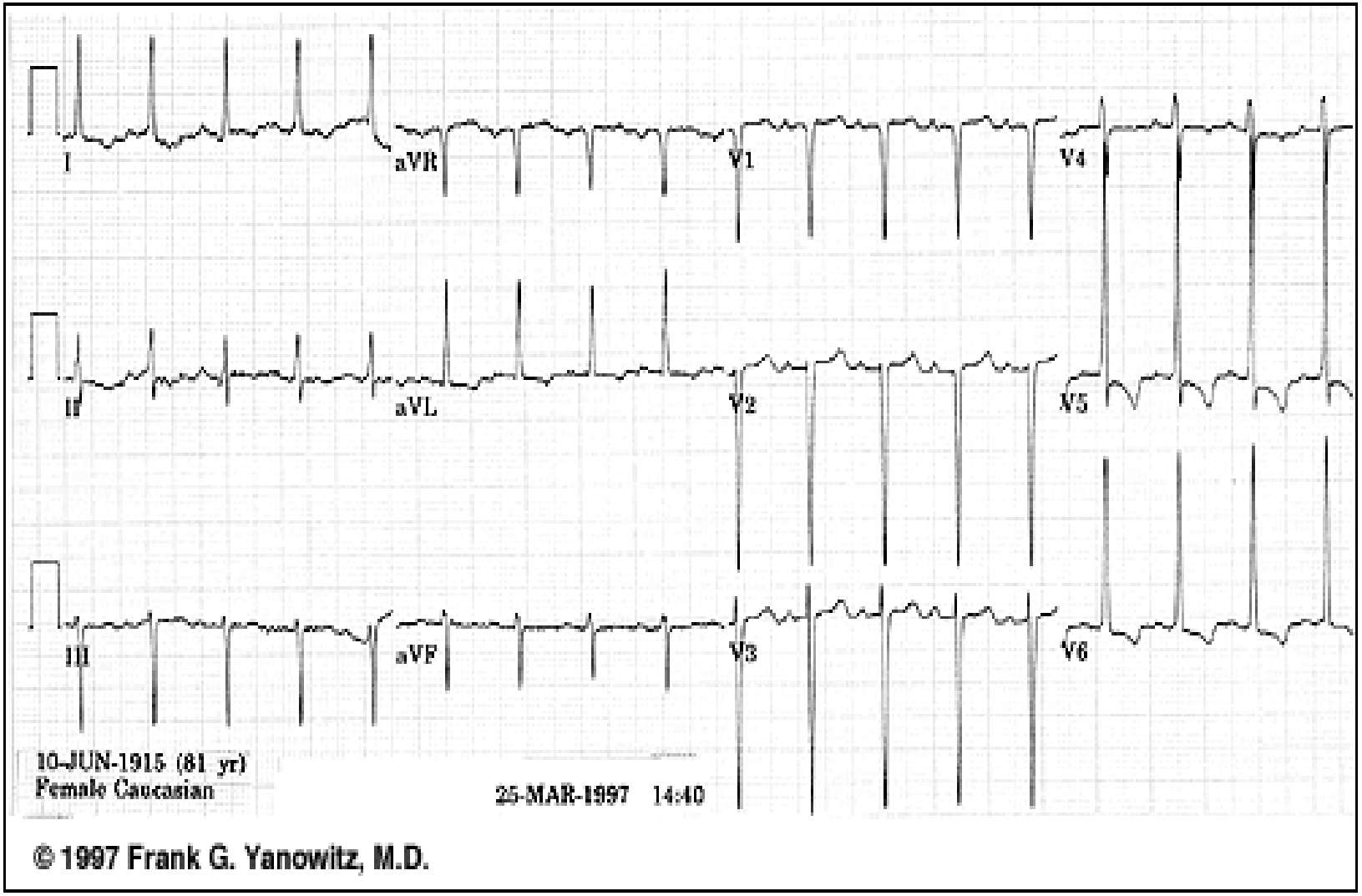

Tanınız nedir ?

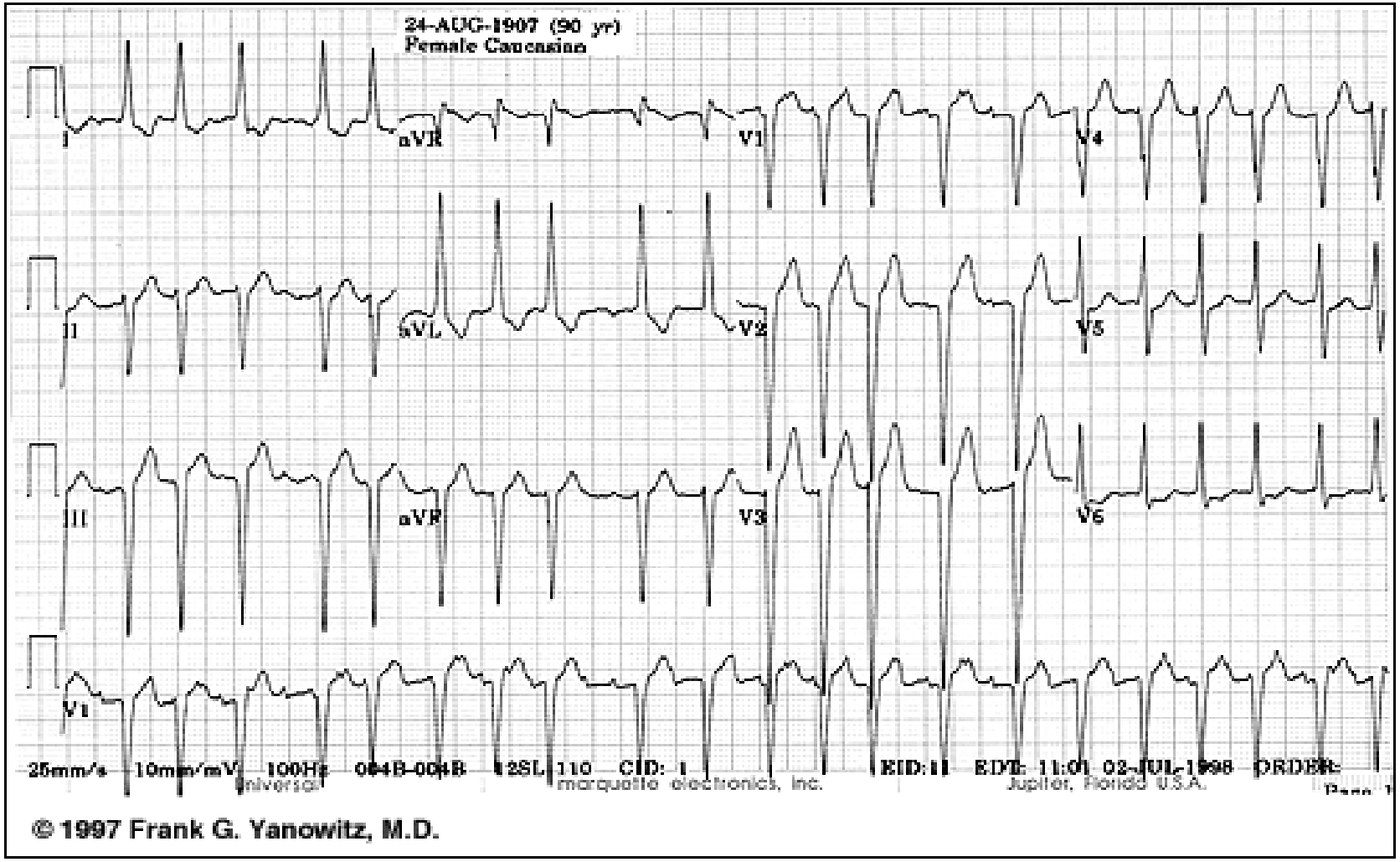

Mulifokal atriyal taşikardi

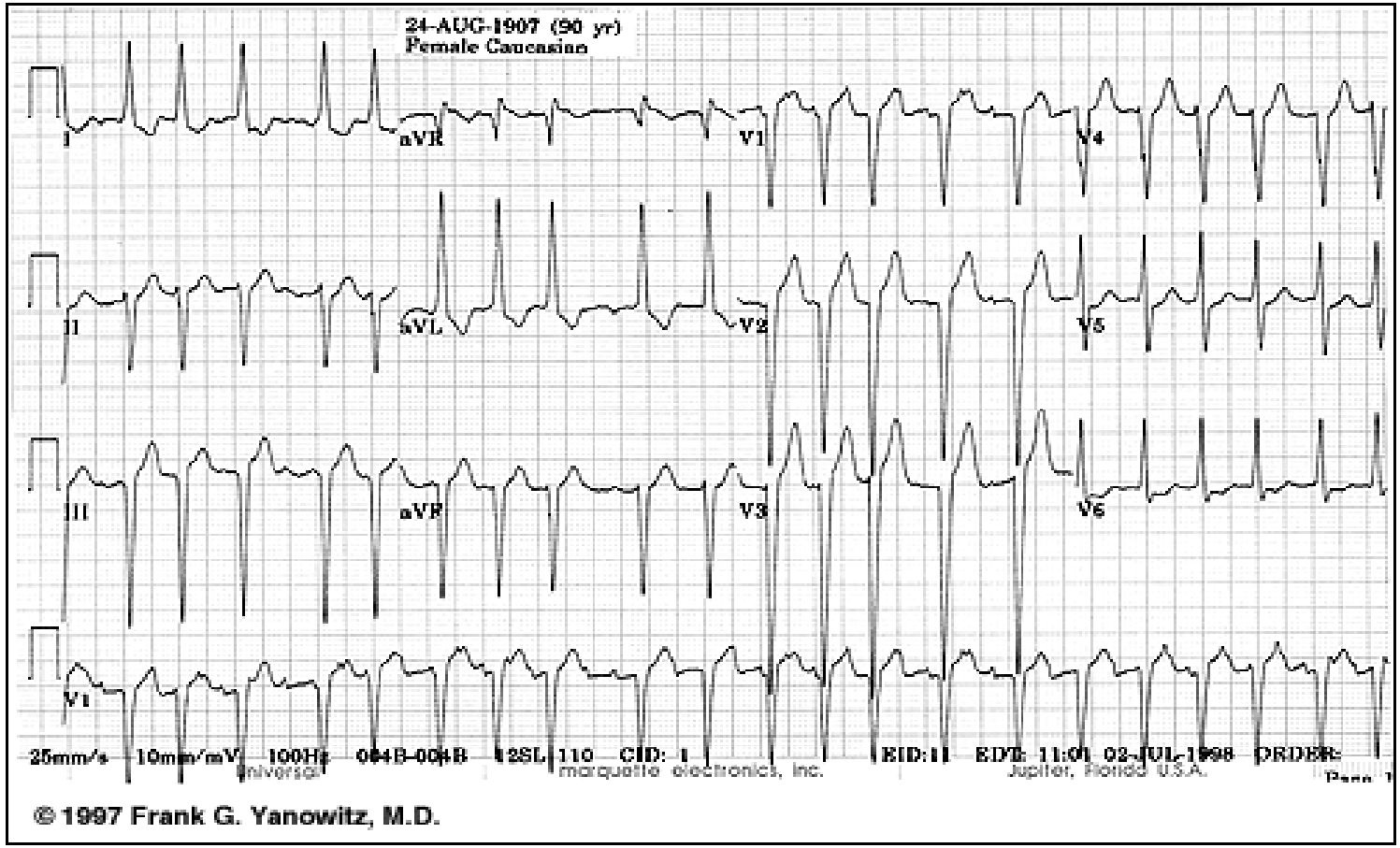

Hız > 100/dk, ≥ 3 değişik morfolojide “p “ dalgası mevcut

Tanınız nedir ?

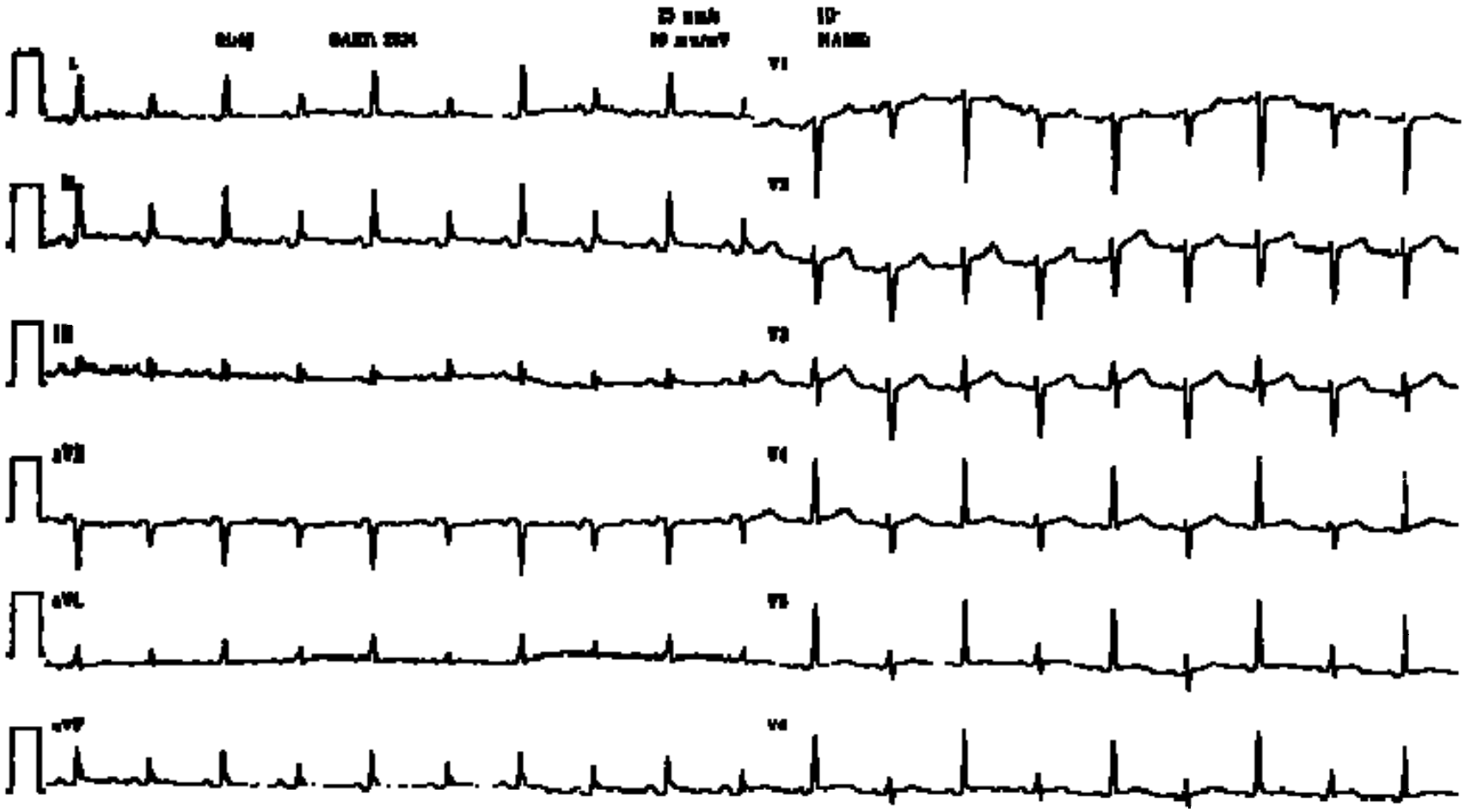

Elektiriksel Alternans, Perikardiyal effüzyon

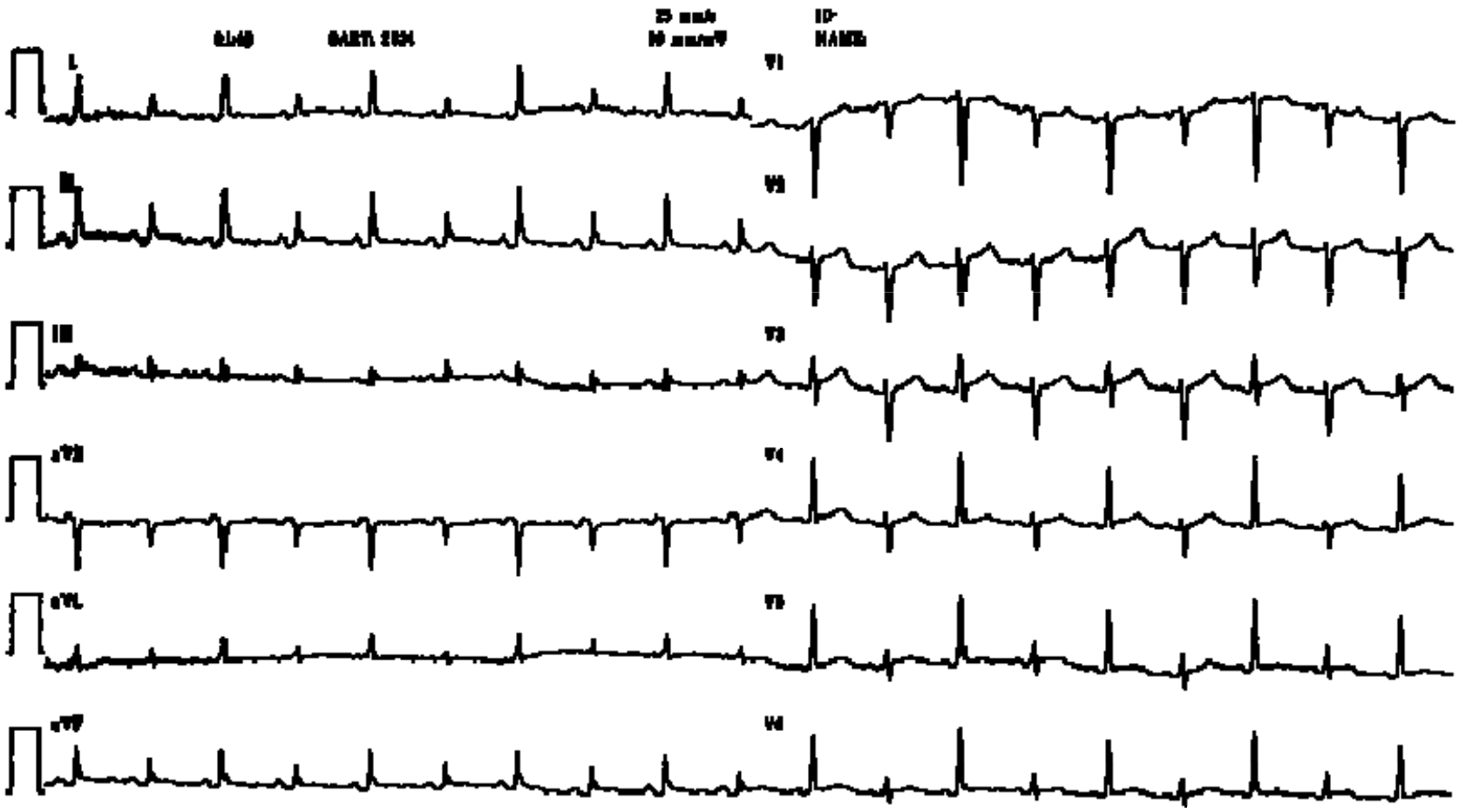

Tanınız nedir ?

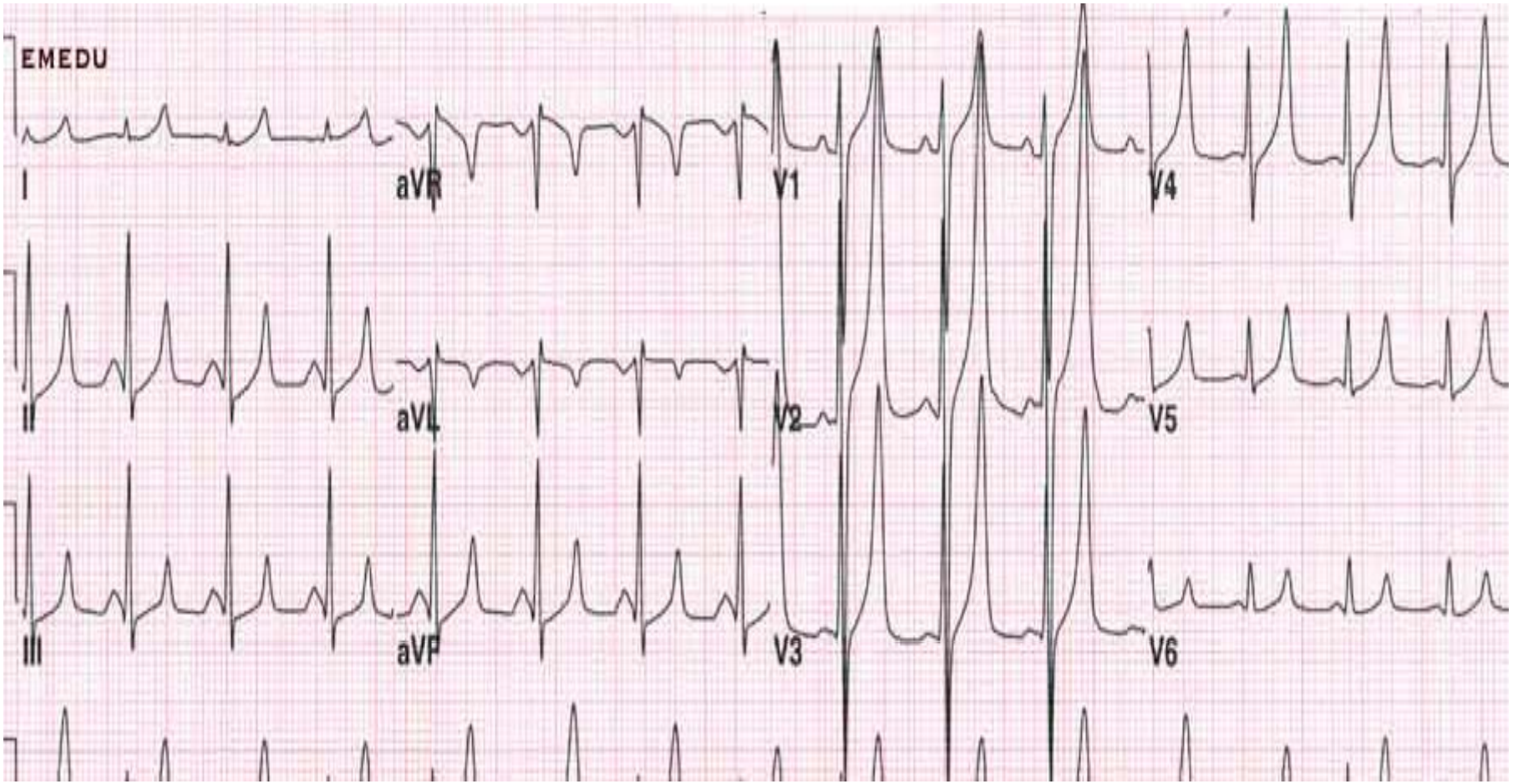

Hiperkalemi

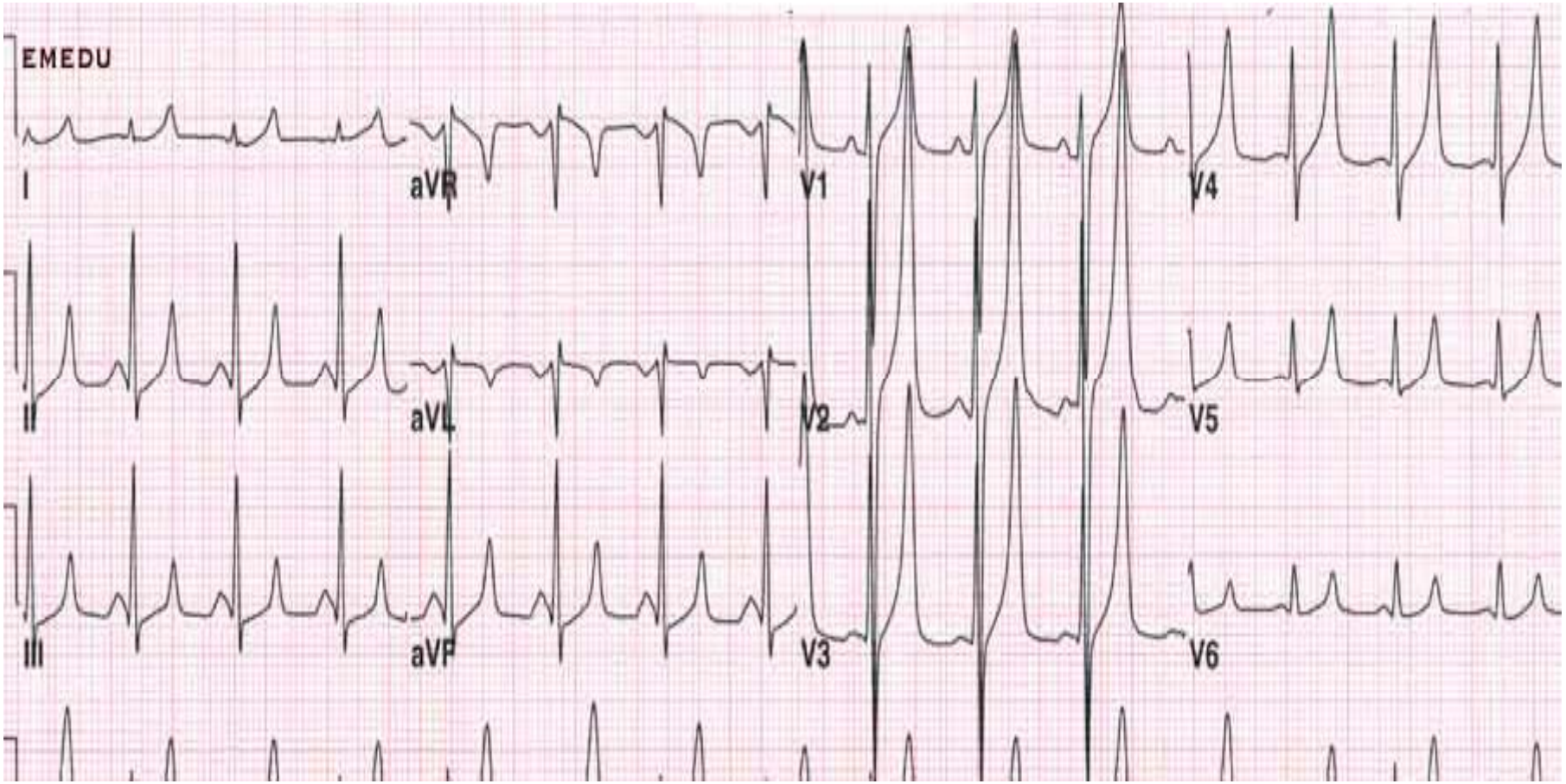

Tanınız nedir ?

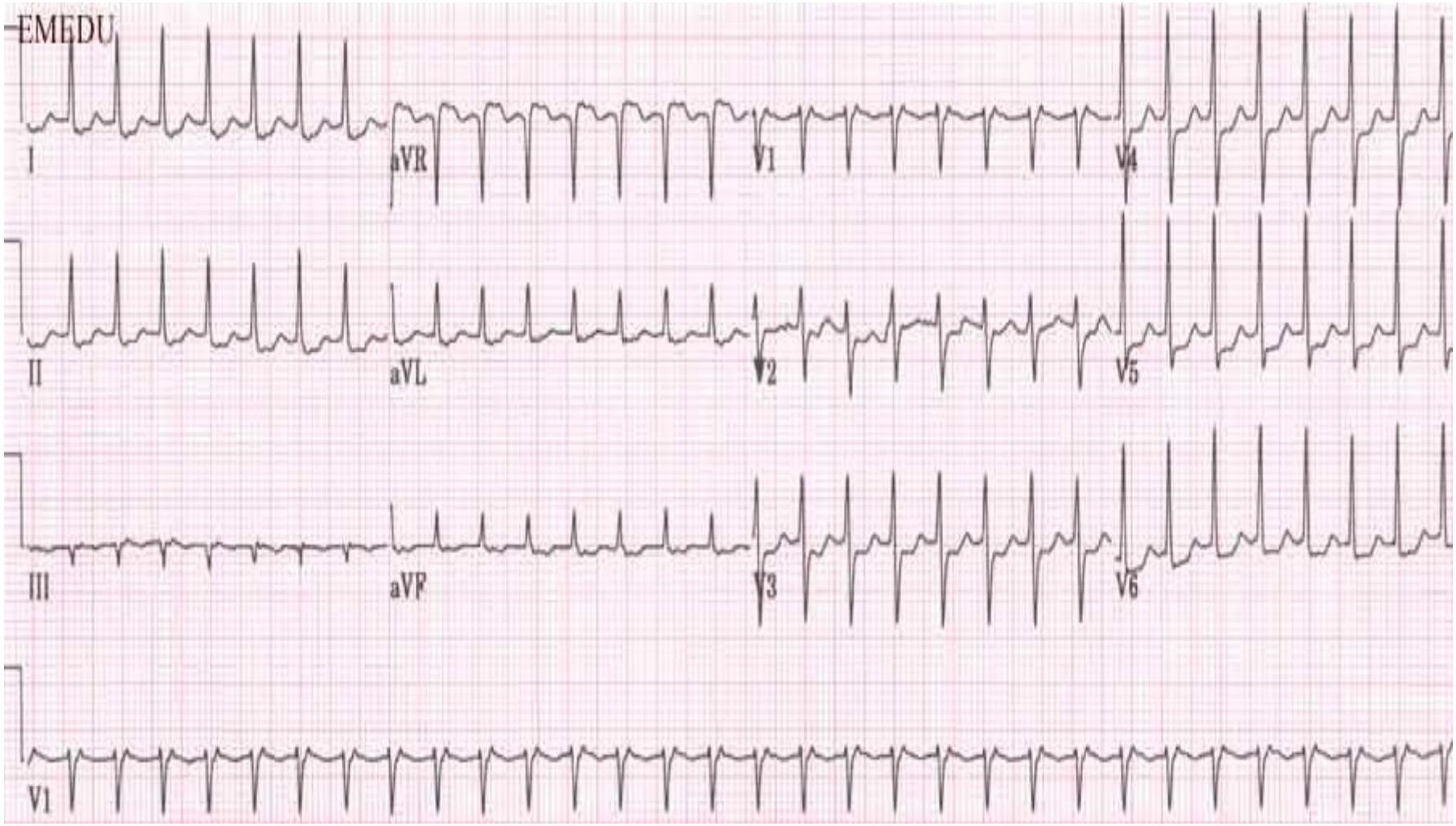

Supraventriküler Taşikardi (taşikardiye bağlı ST depresyonları)

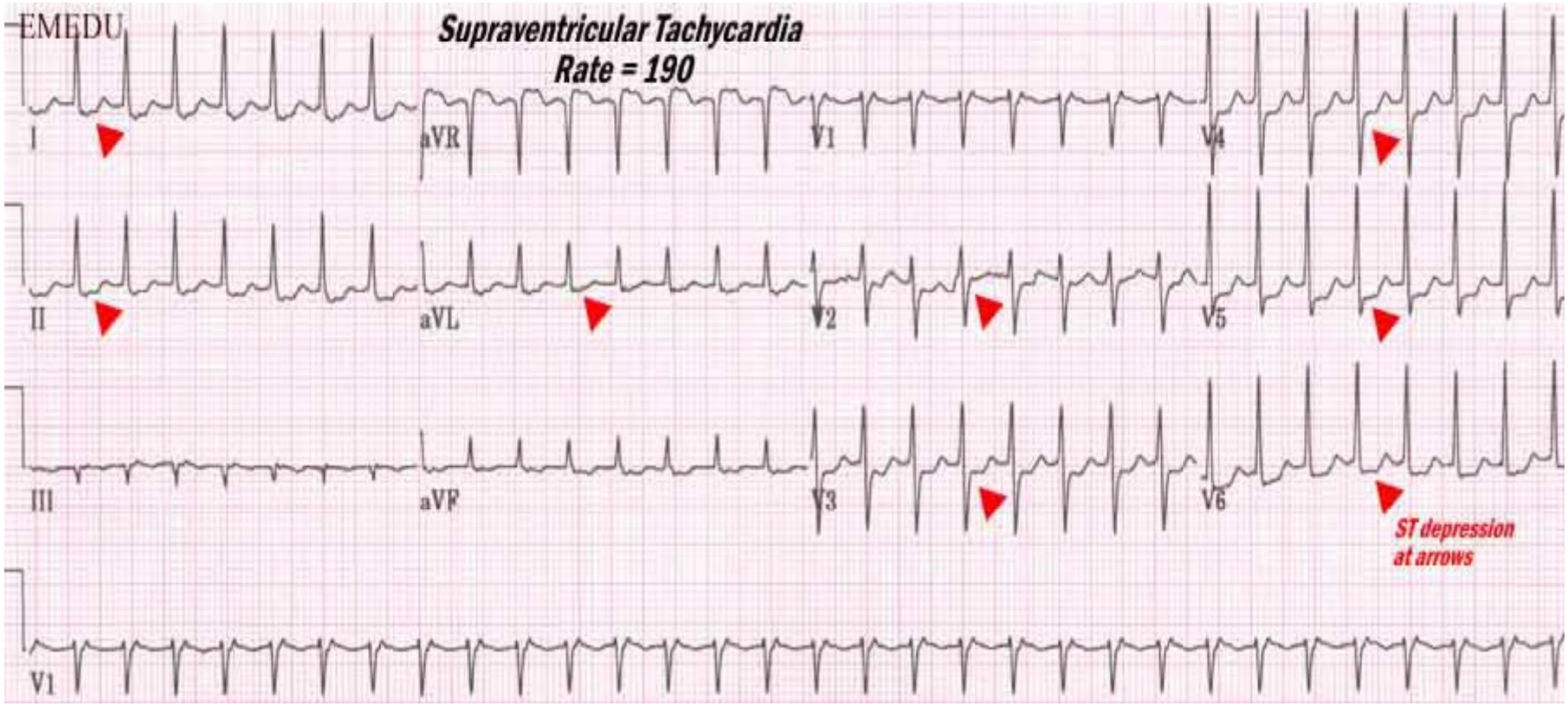

Tanınız nedir ?

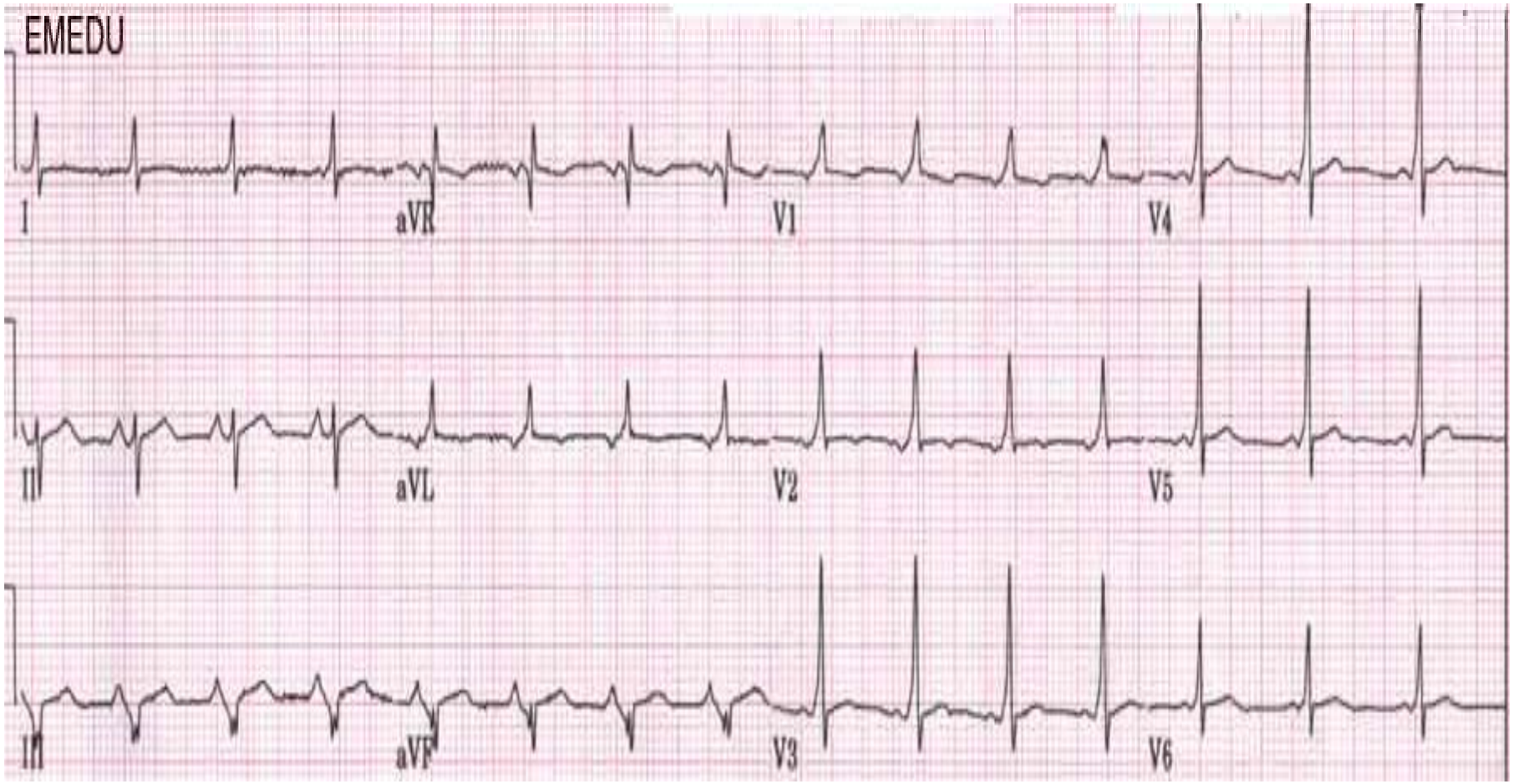

Wolf-Parkinson-White Sendromu

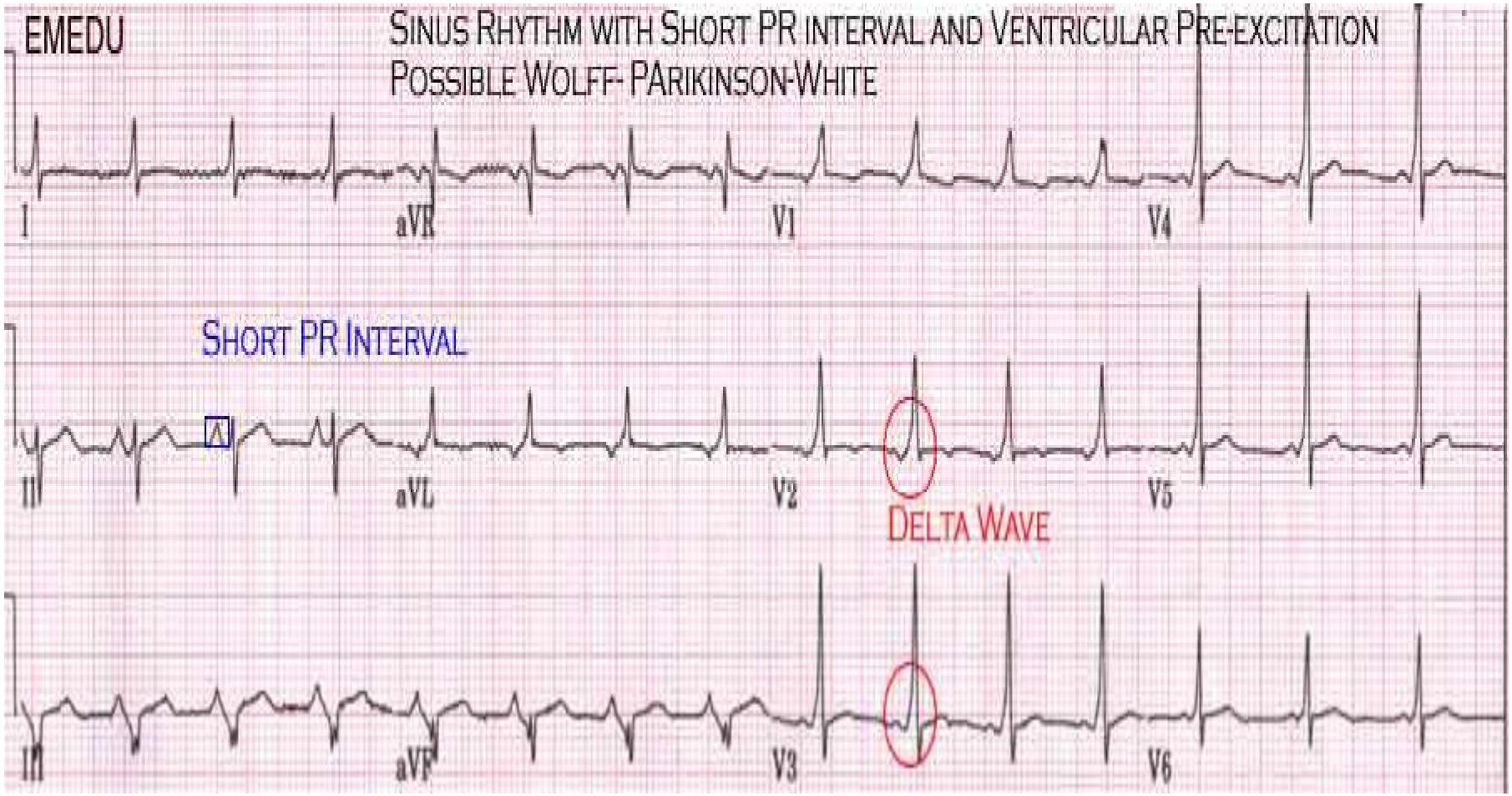

Tanınız nedir ?

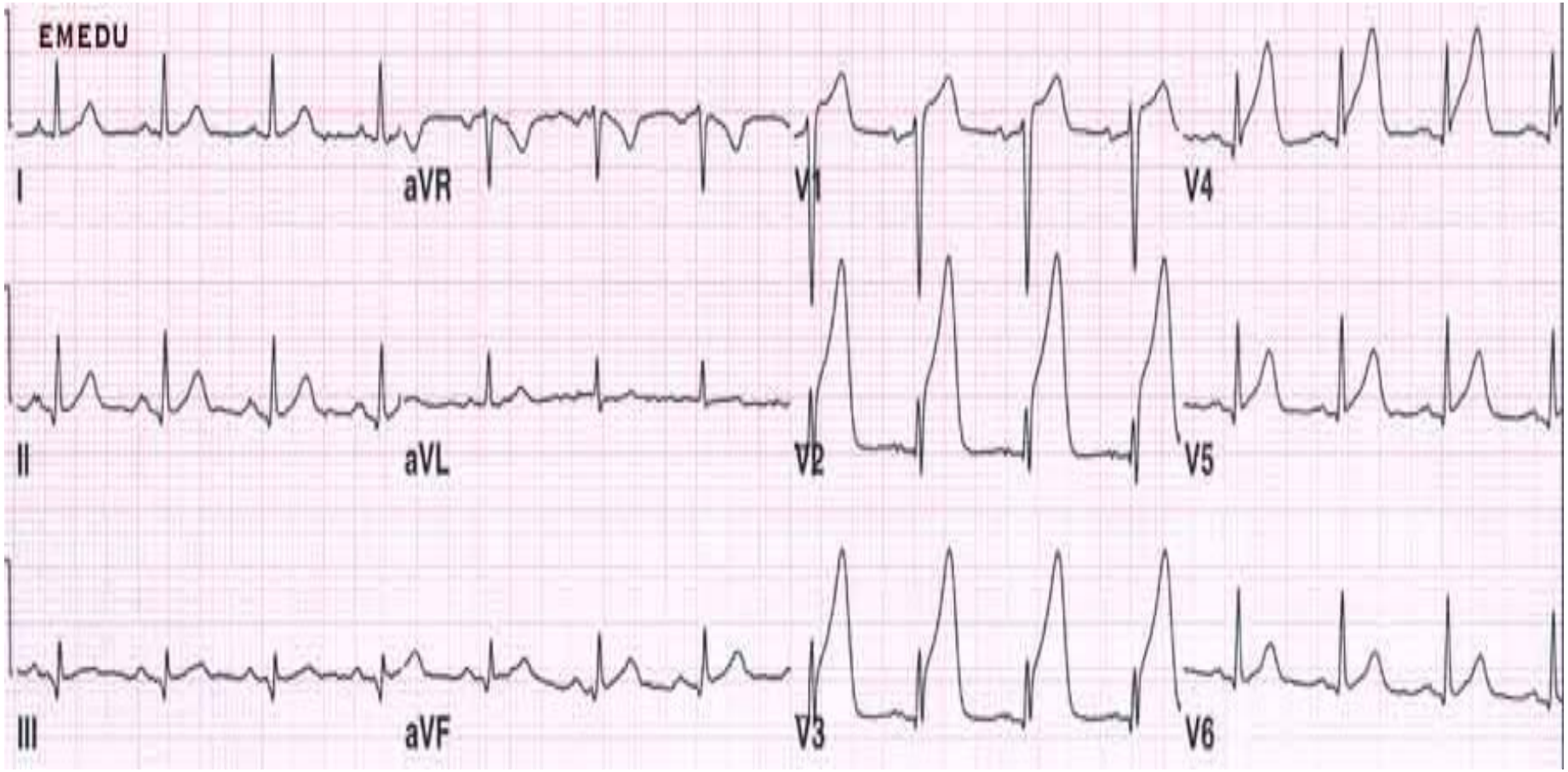

AKUT Anteroseptal Miyokard Enfarktüsü

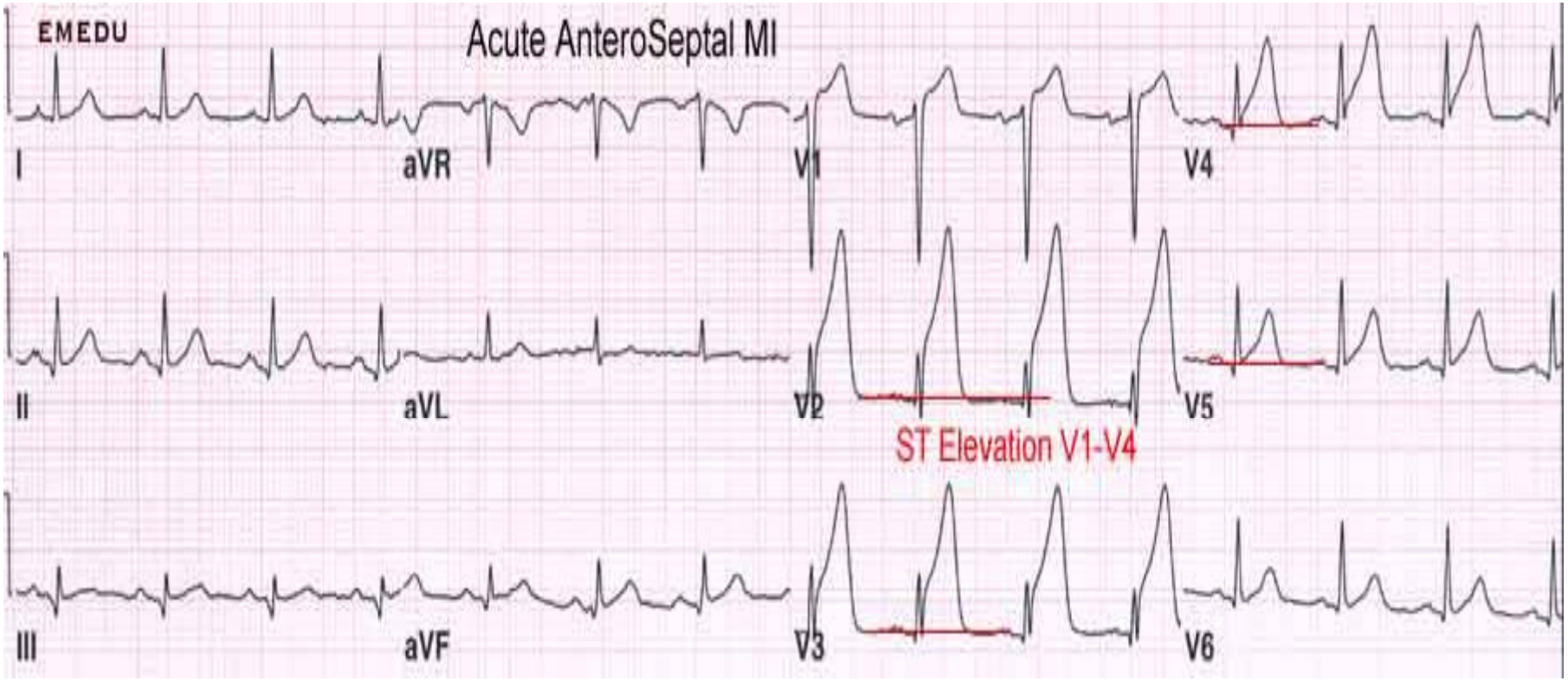

Tanınız nedir ?

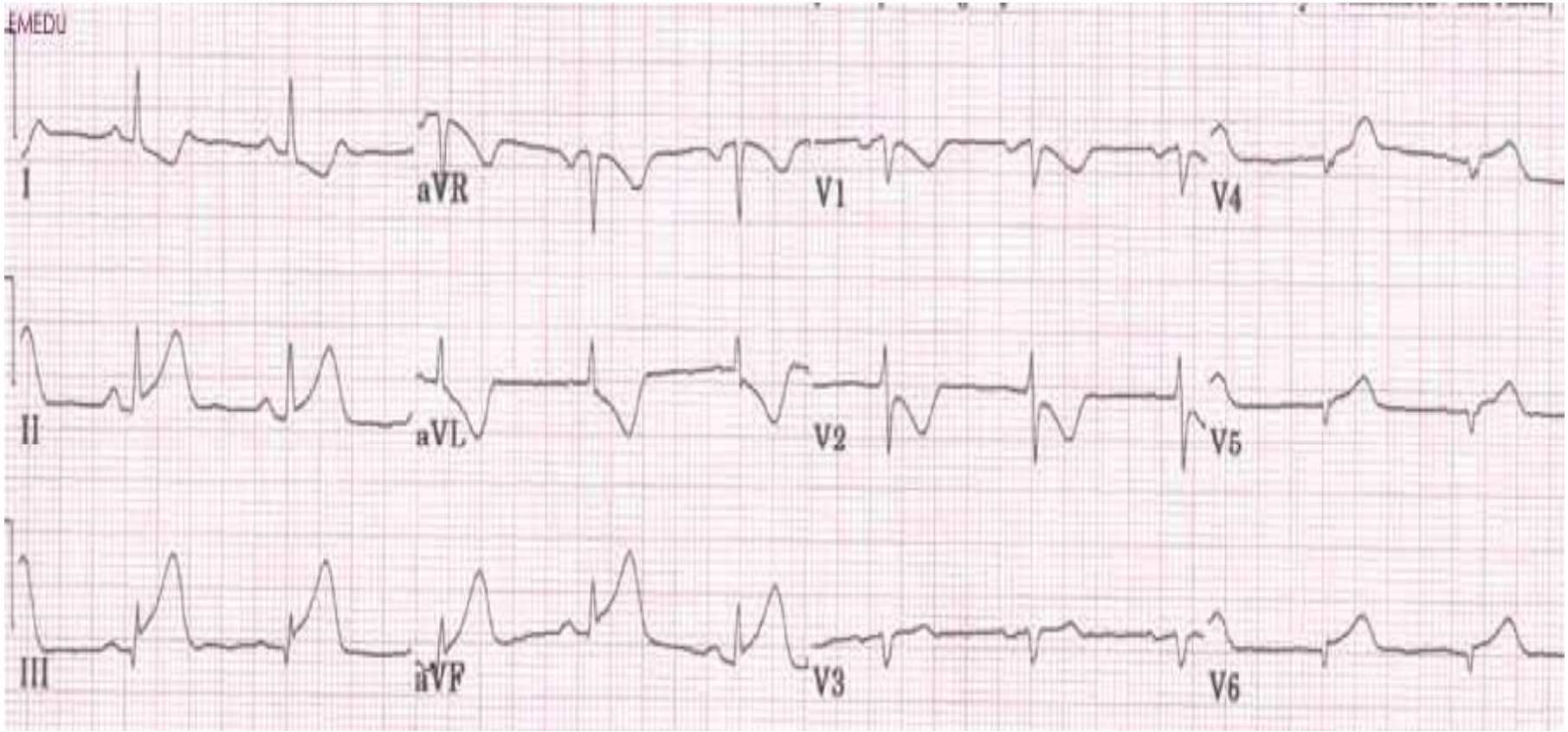

Akut inferior miyokard enfarktüsü

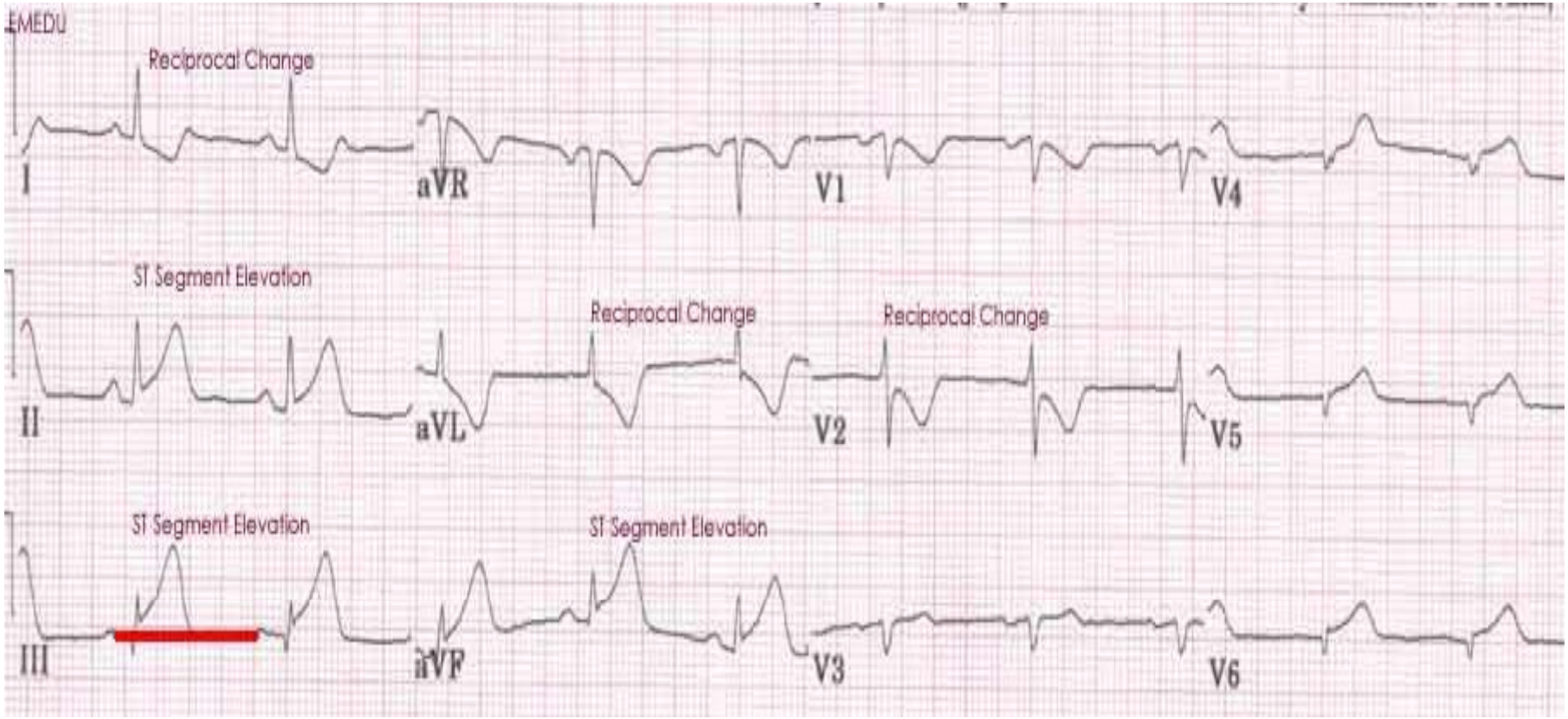

Tanınız nedir ?

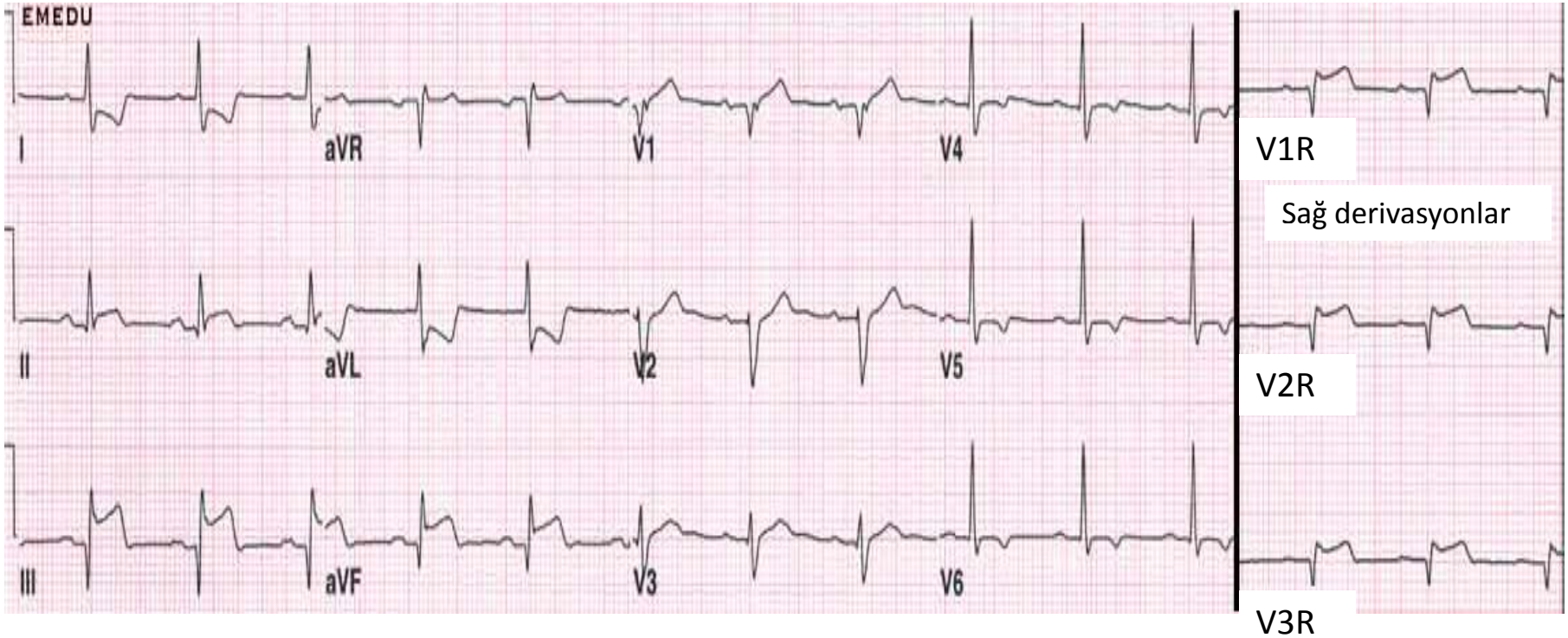

Sağ ventrikül tutulumu olan akut inferior miyokard enfarktüsü

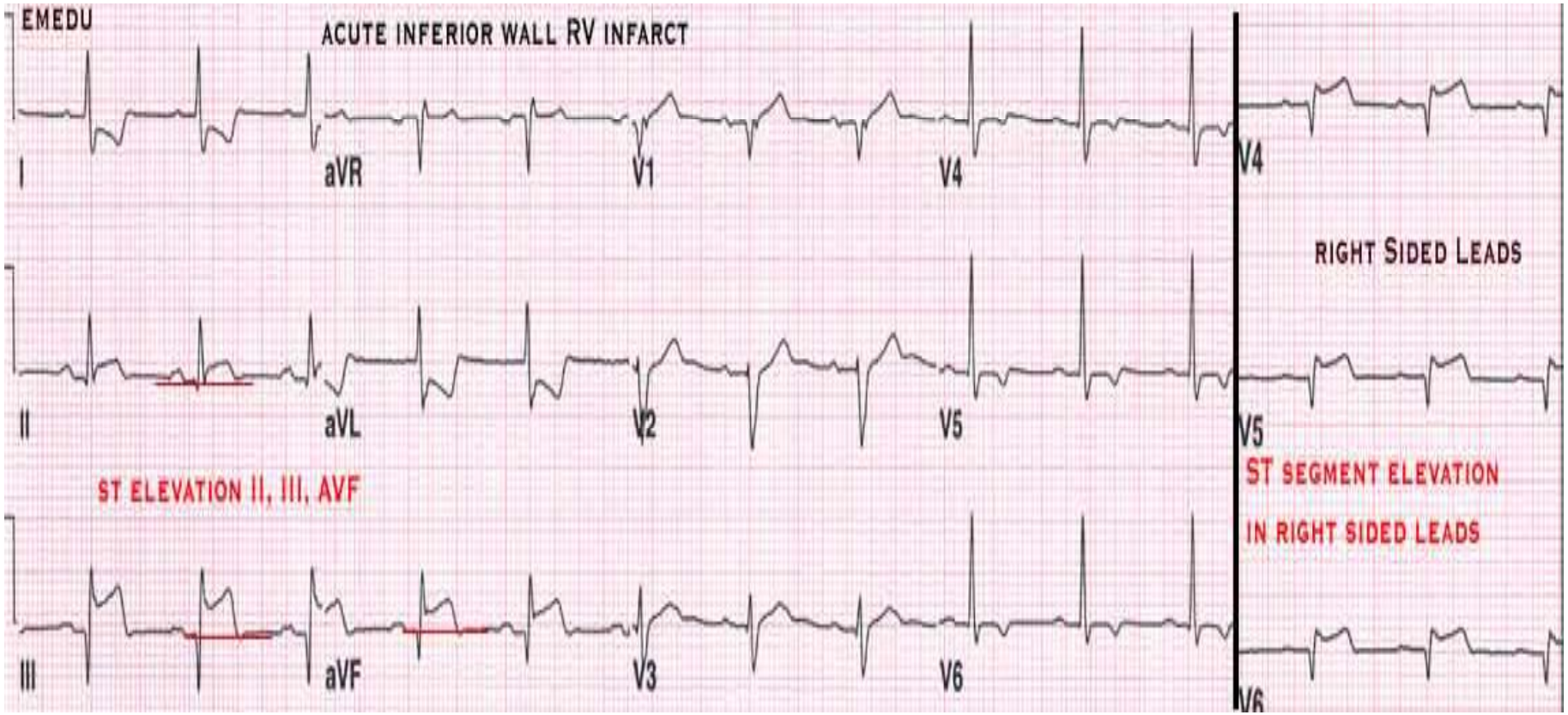

Tanınız nedir ?

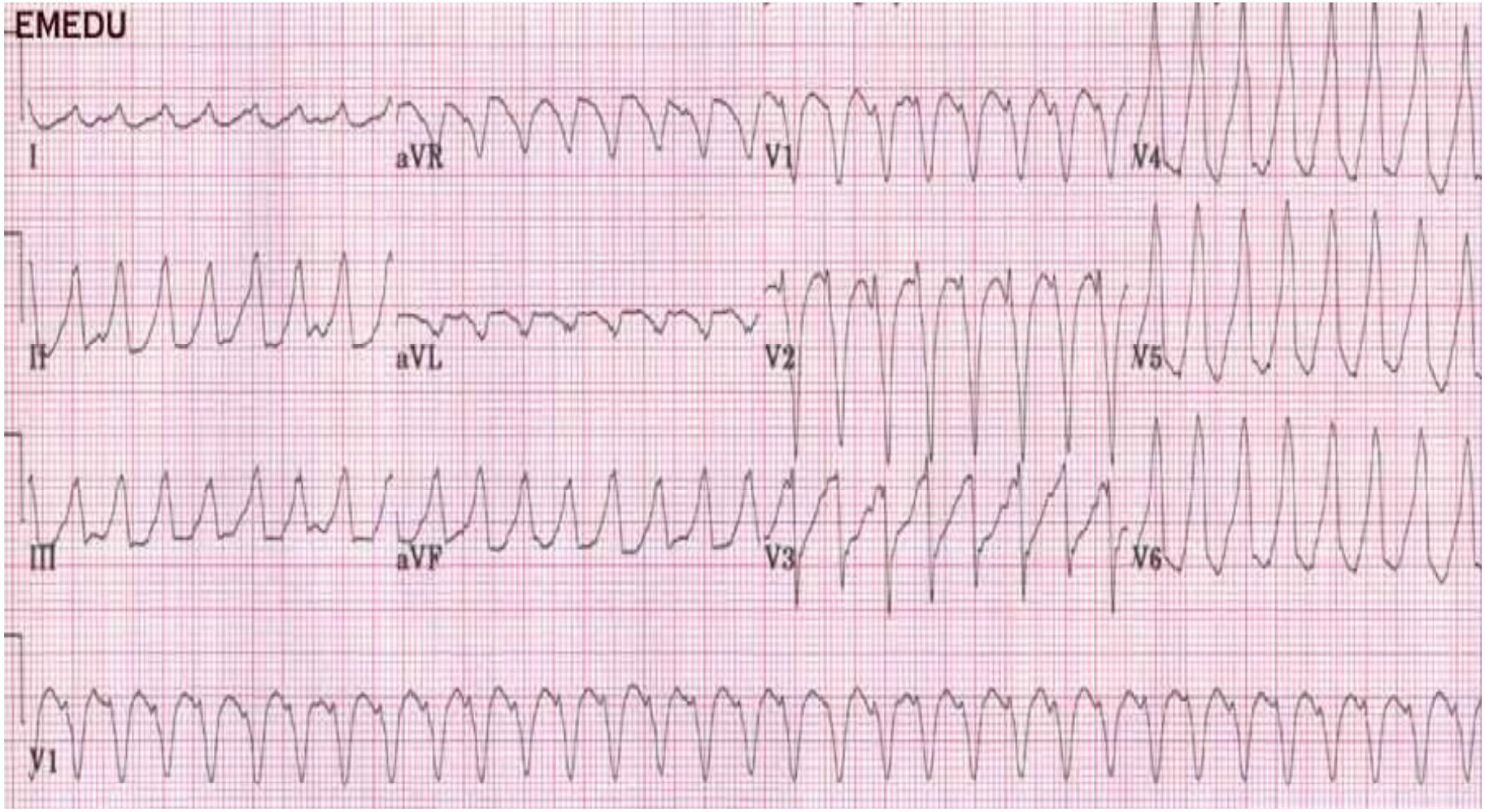

Ventriküler Taşikardi

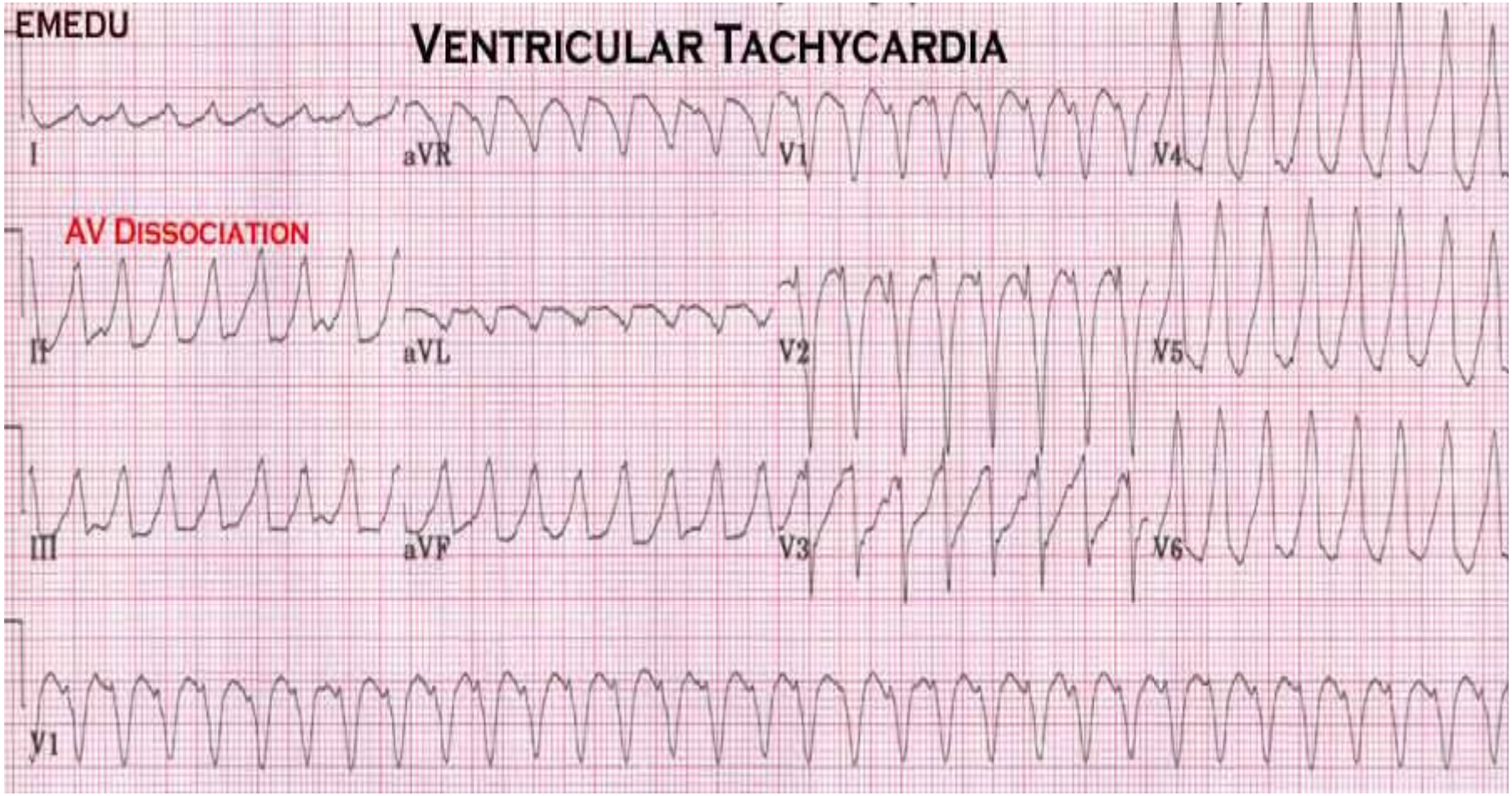

Ventriküler Taşikardi

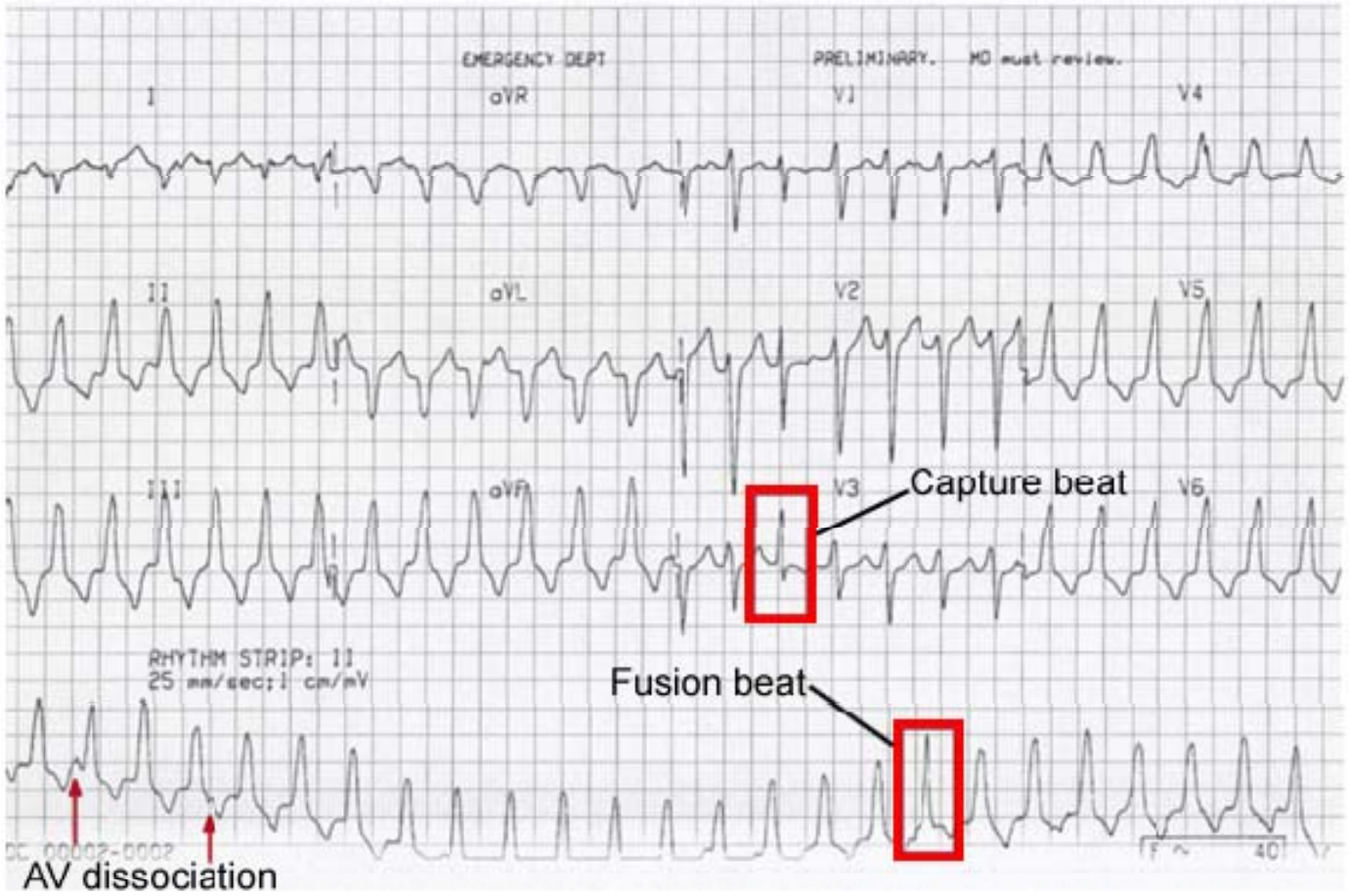

Fusion/Capture Beats/AV Dissociation

Tanınız nedir ?

Sinoatriyal Exit Blok

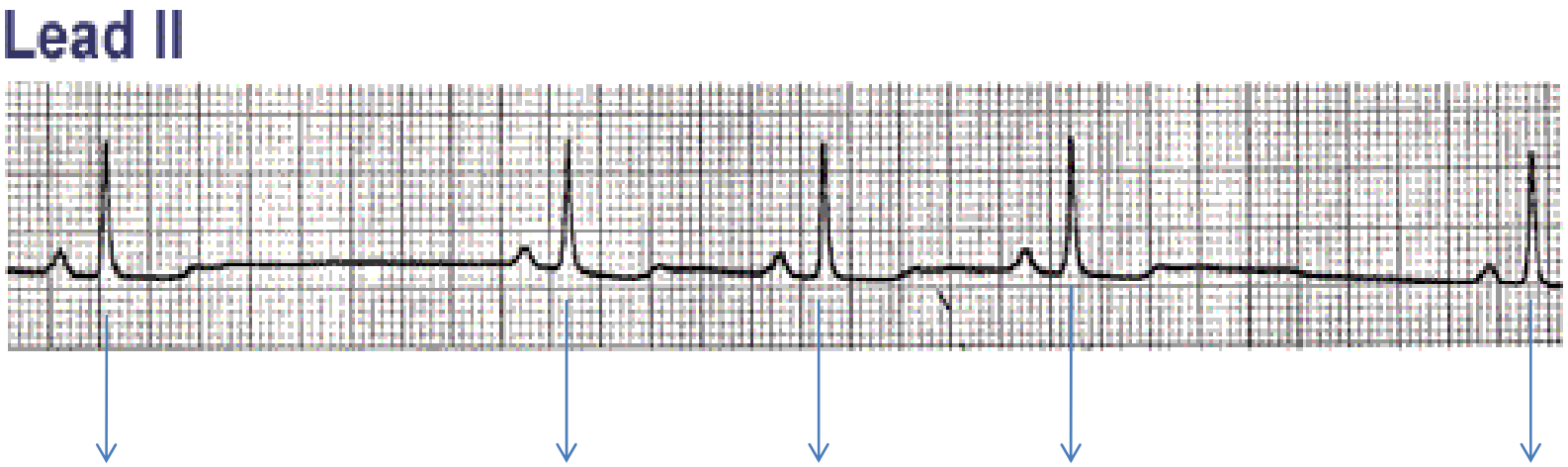

Tanınız nedir ?

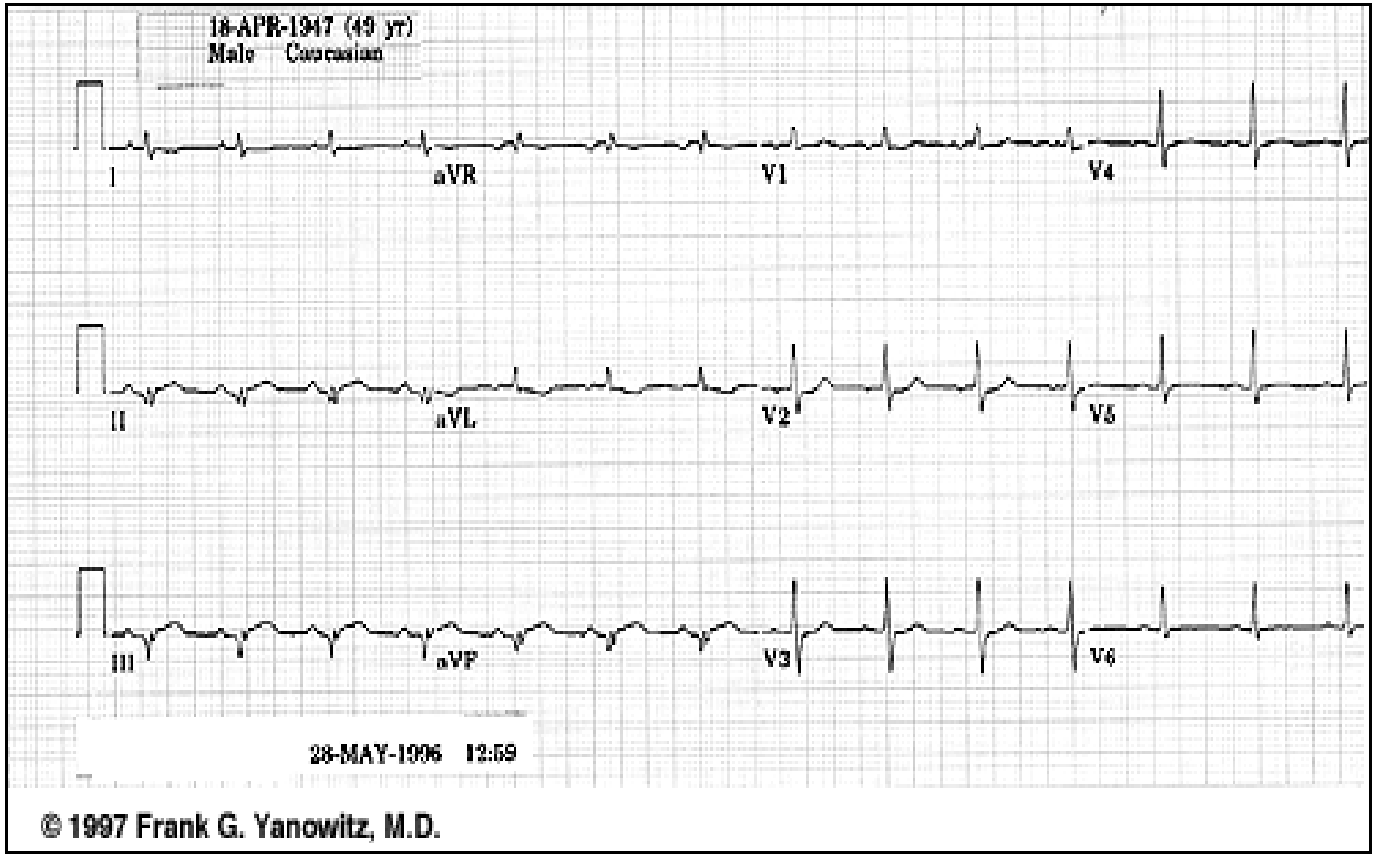

Geçirilmiş (eski) inferoposterior MI

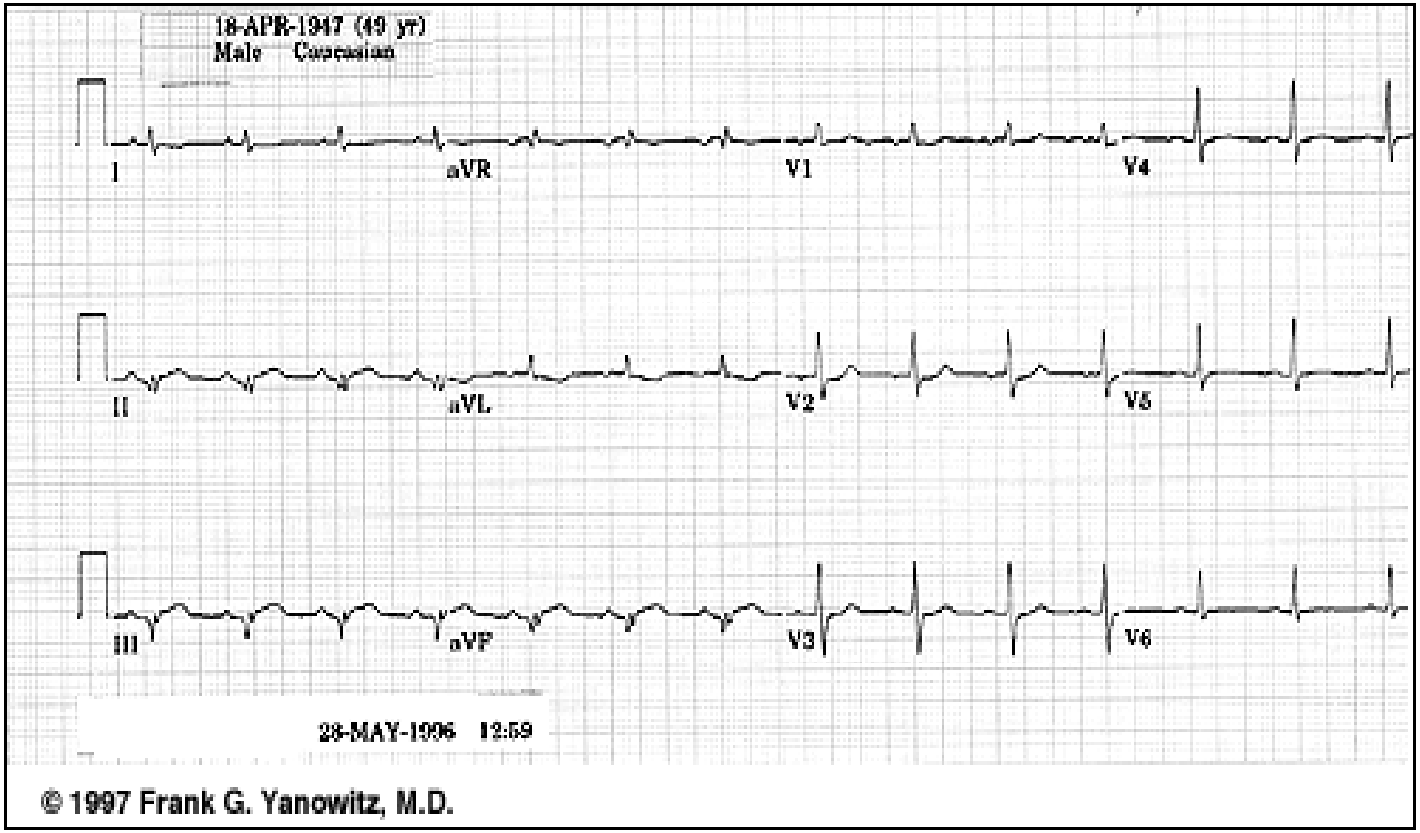

Tanınız nedir ?

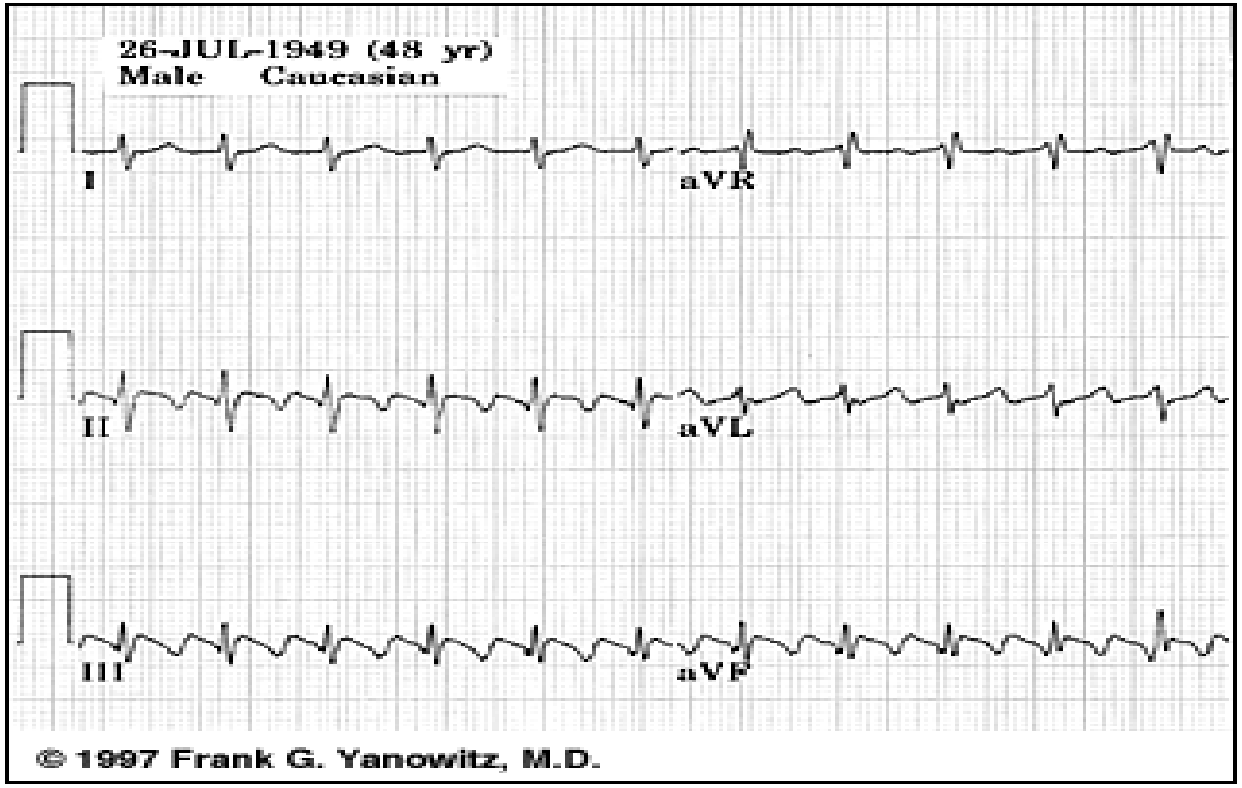

Atriyal Flatter (2:1 geçişli)

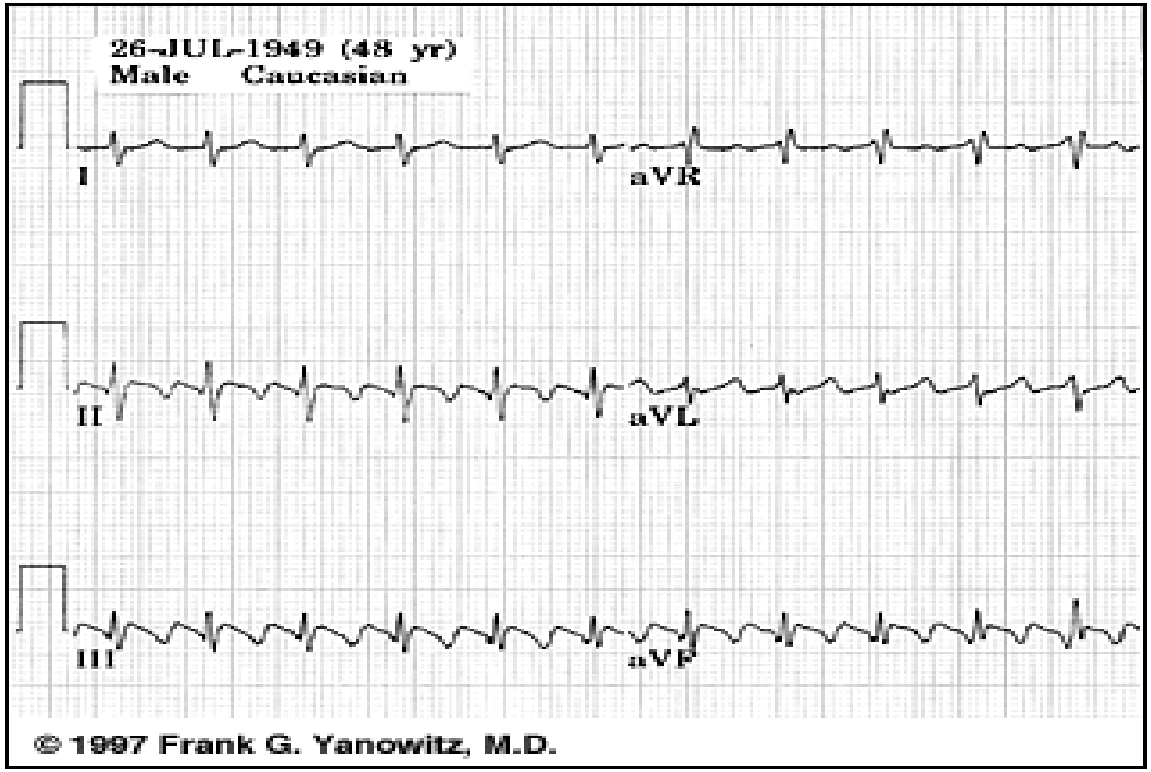

Tanınız nedir ?

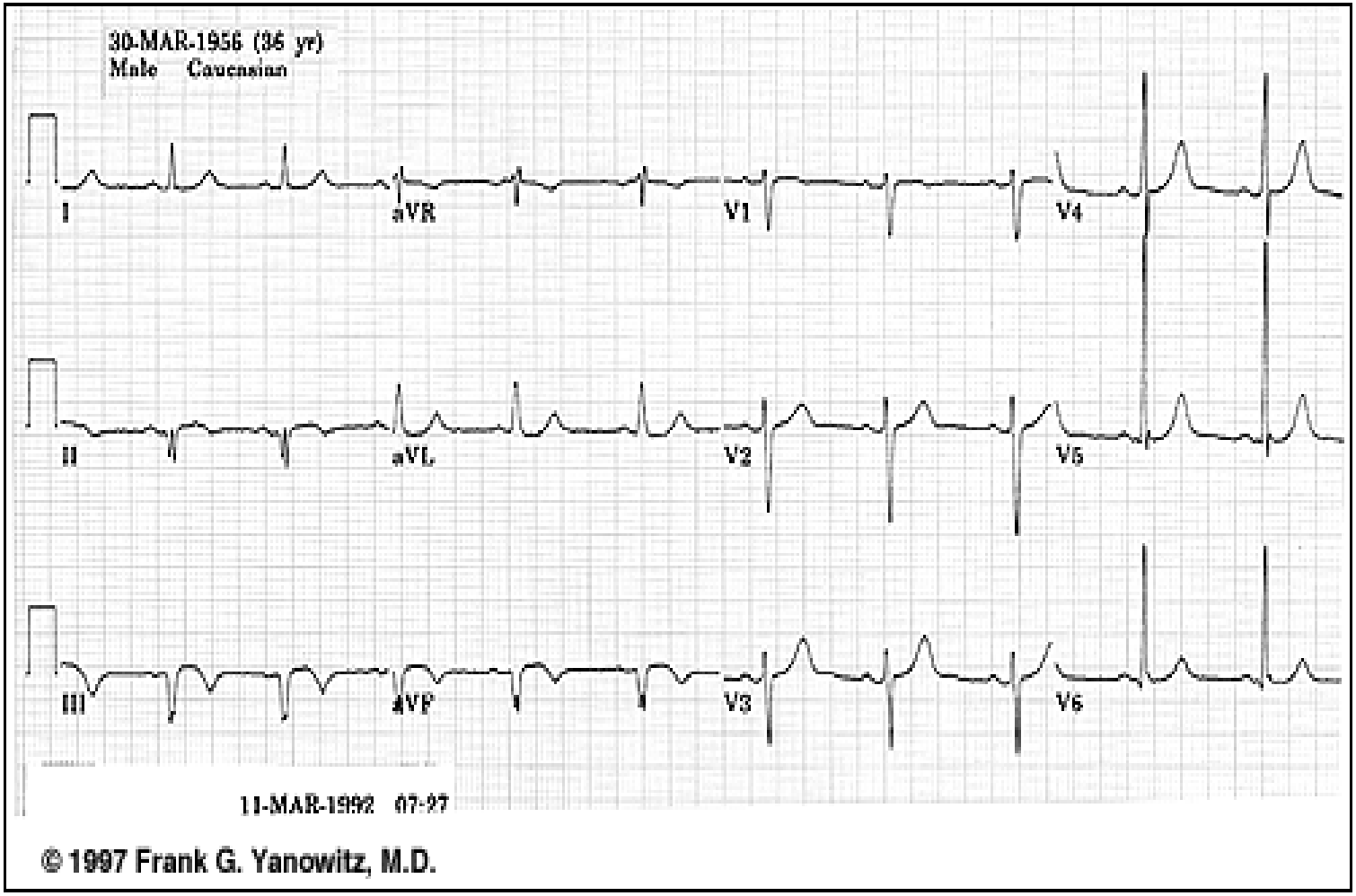

Subakut (yerleşmiş) inferior MI

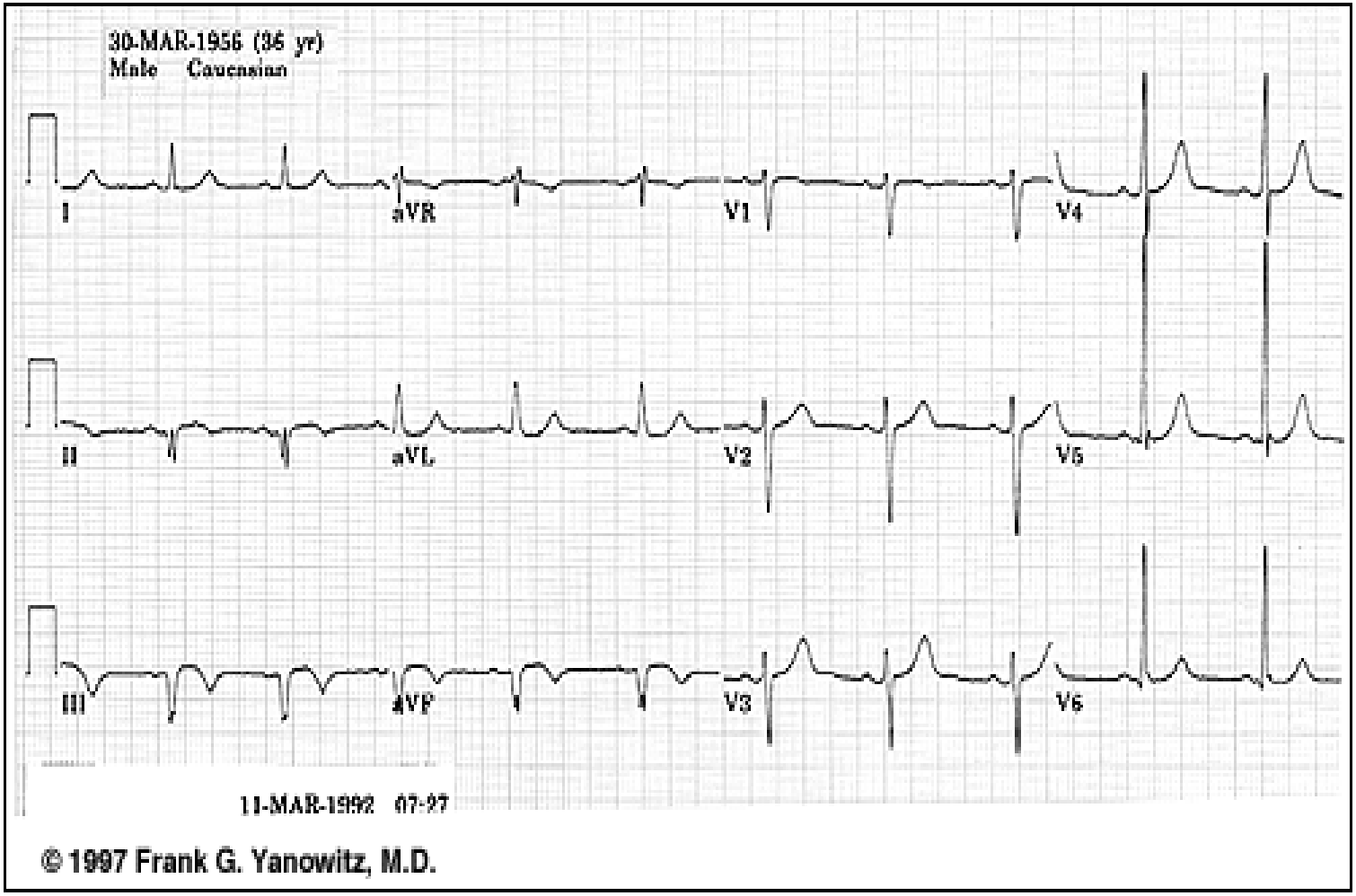

Tanınız nedir ?

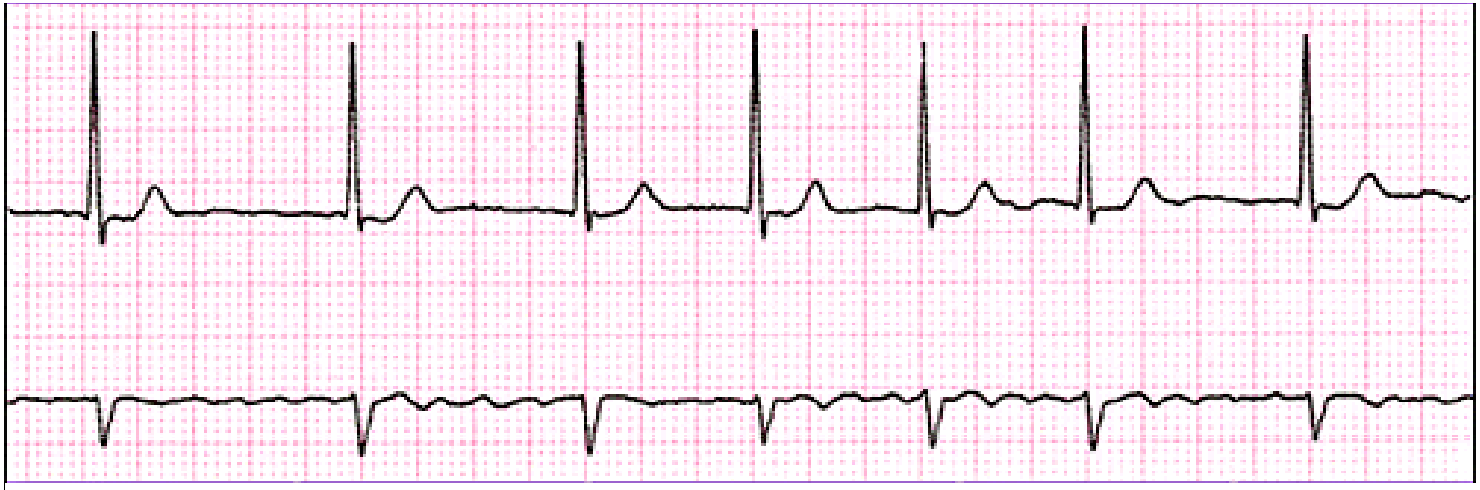

Normal ventriküler yanıtlı Atriyal fibrilasyon

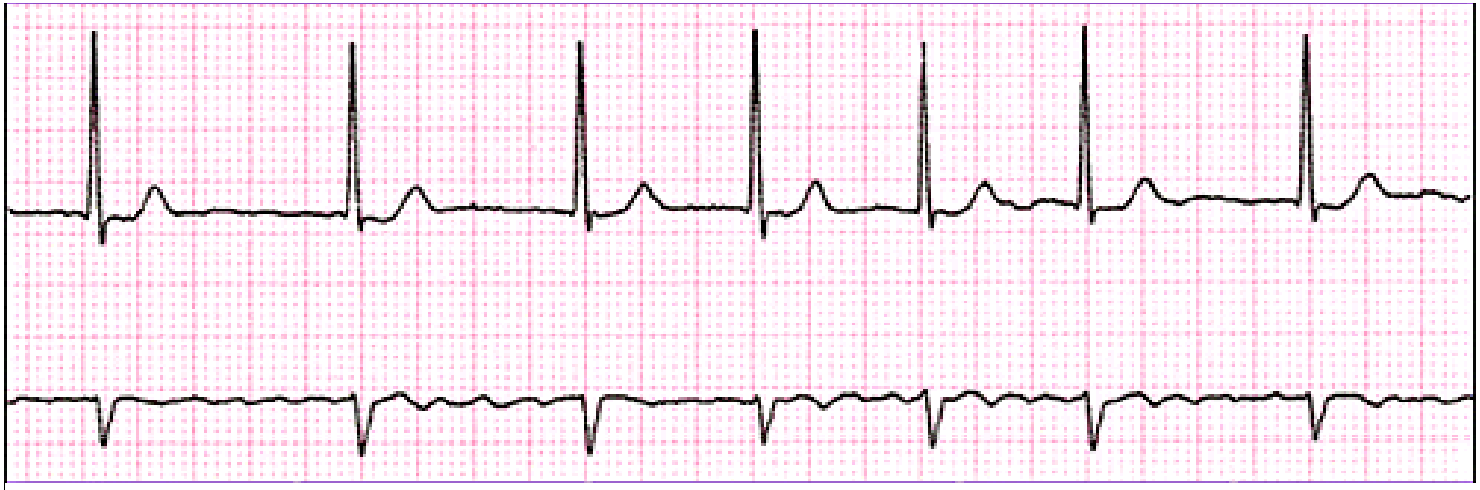

Tanınız nedir ?

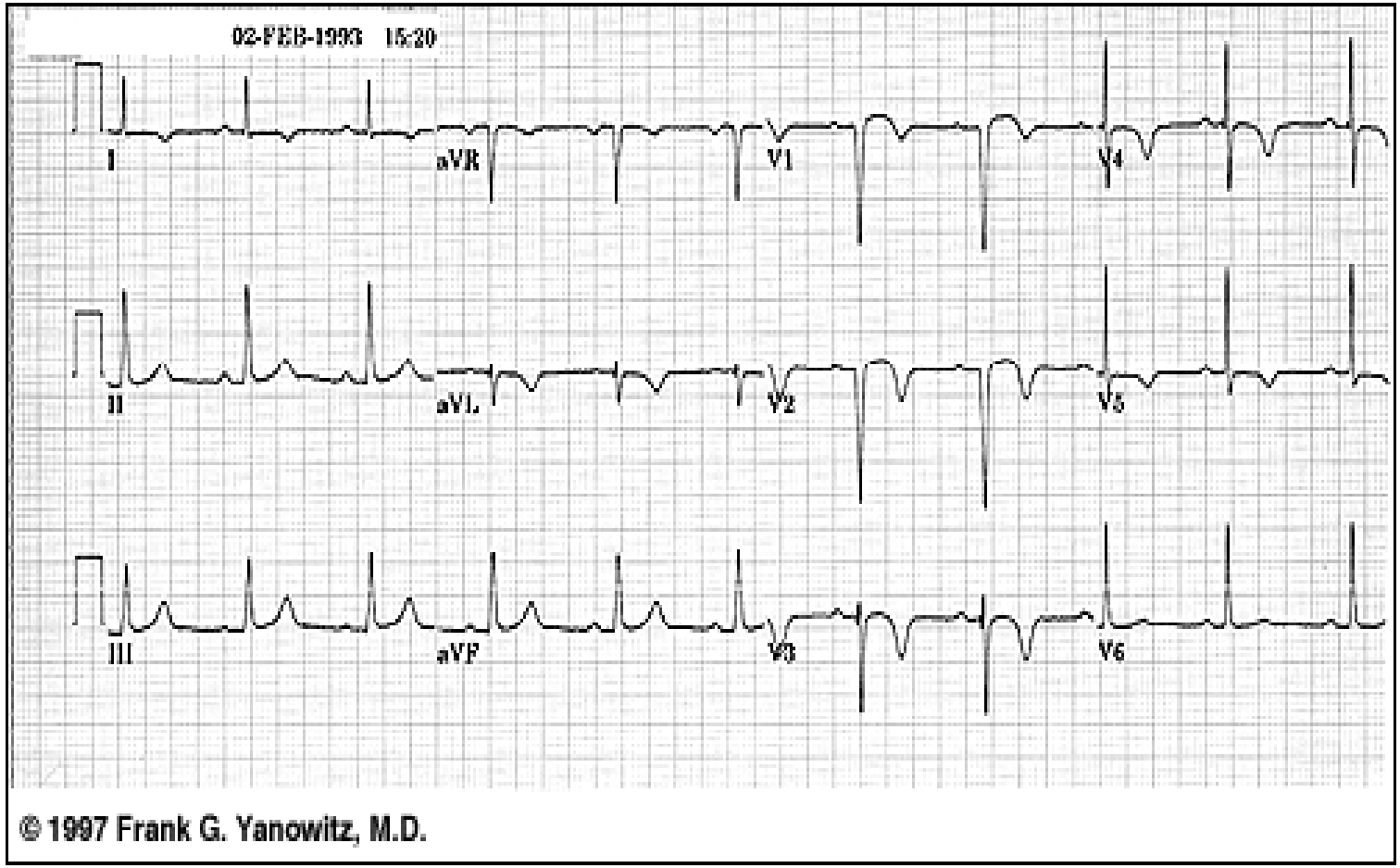

Subakut (yerleşmiş) anteroseptal MI

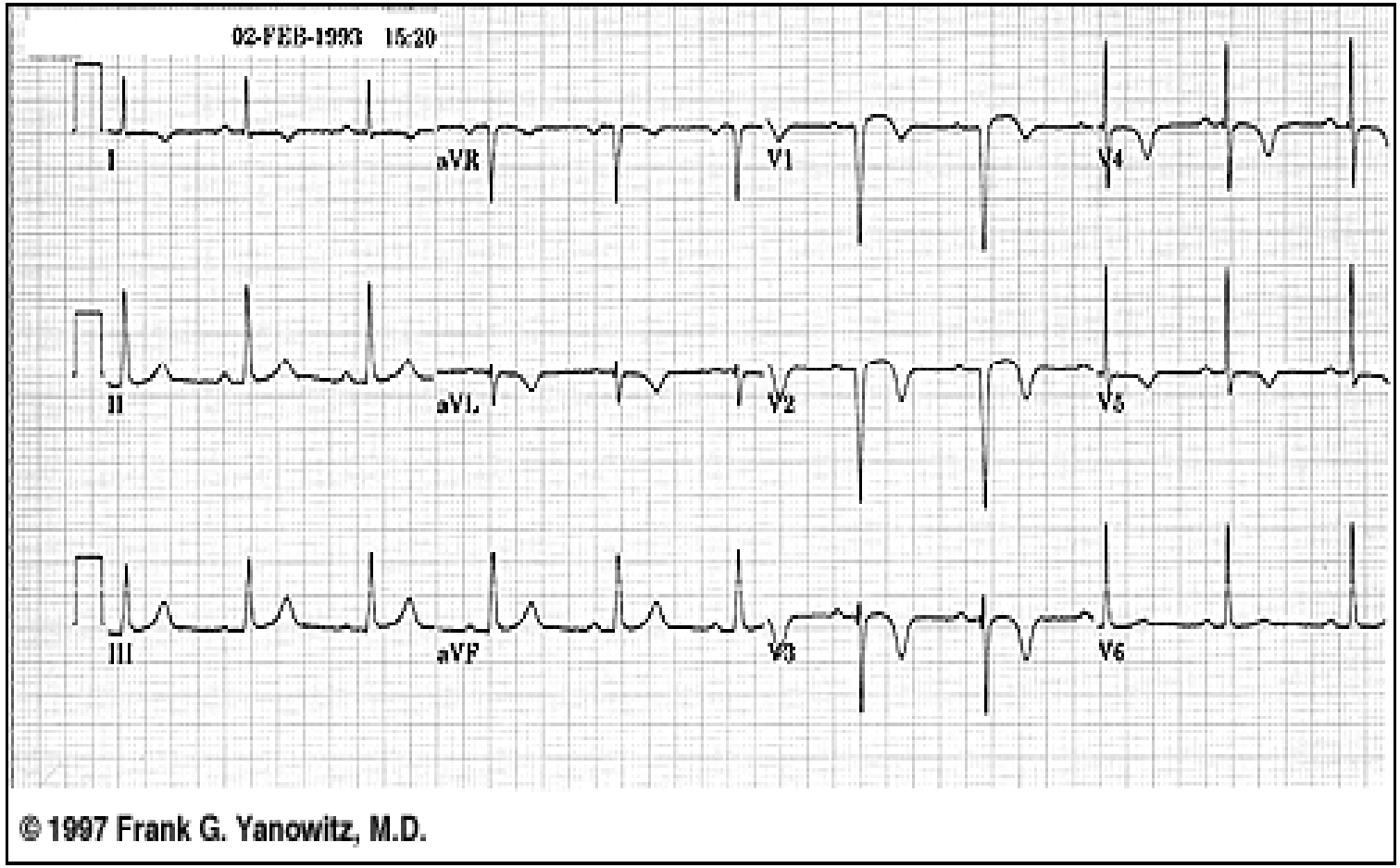

Tanınız nedir ?

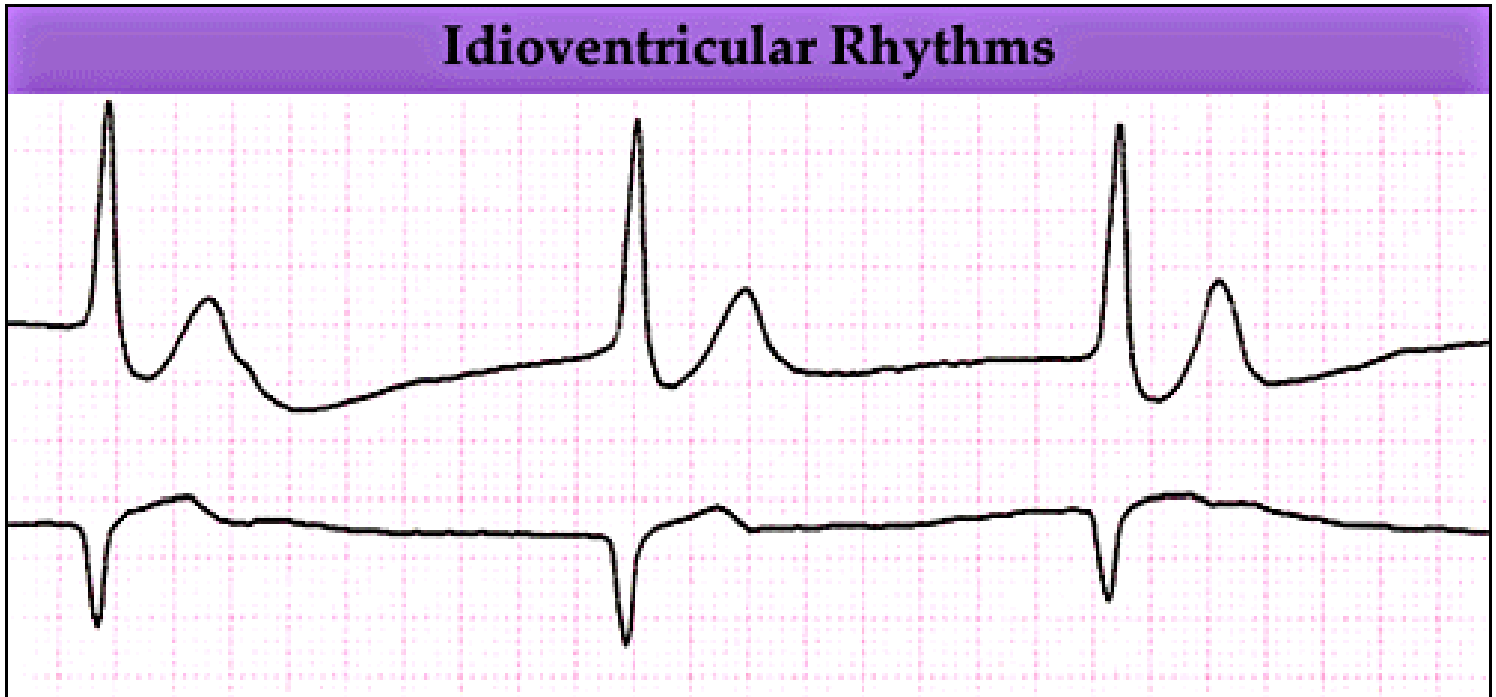

Heart Rate	Rhythm	P Wave	PR interval (in seconds)	QRS (in seconds)
20-40	Regular	Absent or not related	N/A	≥ .12

İdioventriküler Ritim

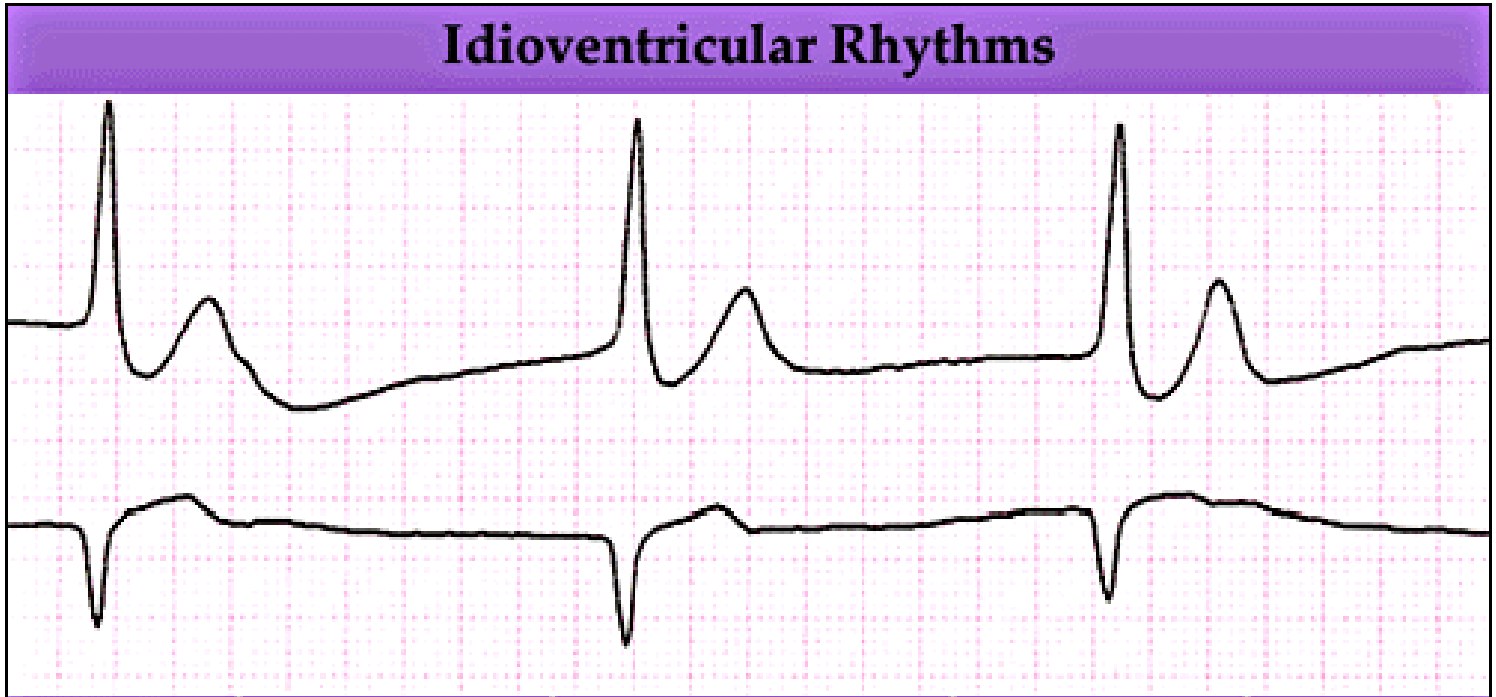

Heart Rate	Rhythm	P Wave	PR interval (in seconds)	QRS (in seconds)
20-40	Regular	Absent or not related	N/A	≥ .12

Tanınız nedir ?

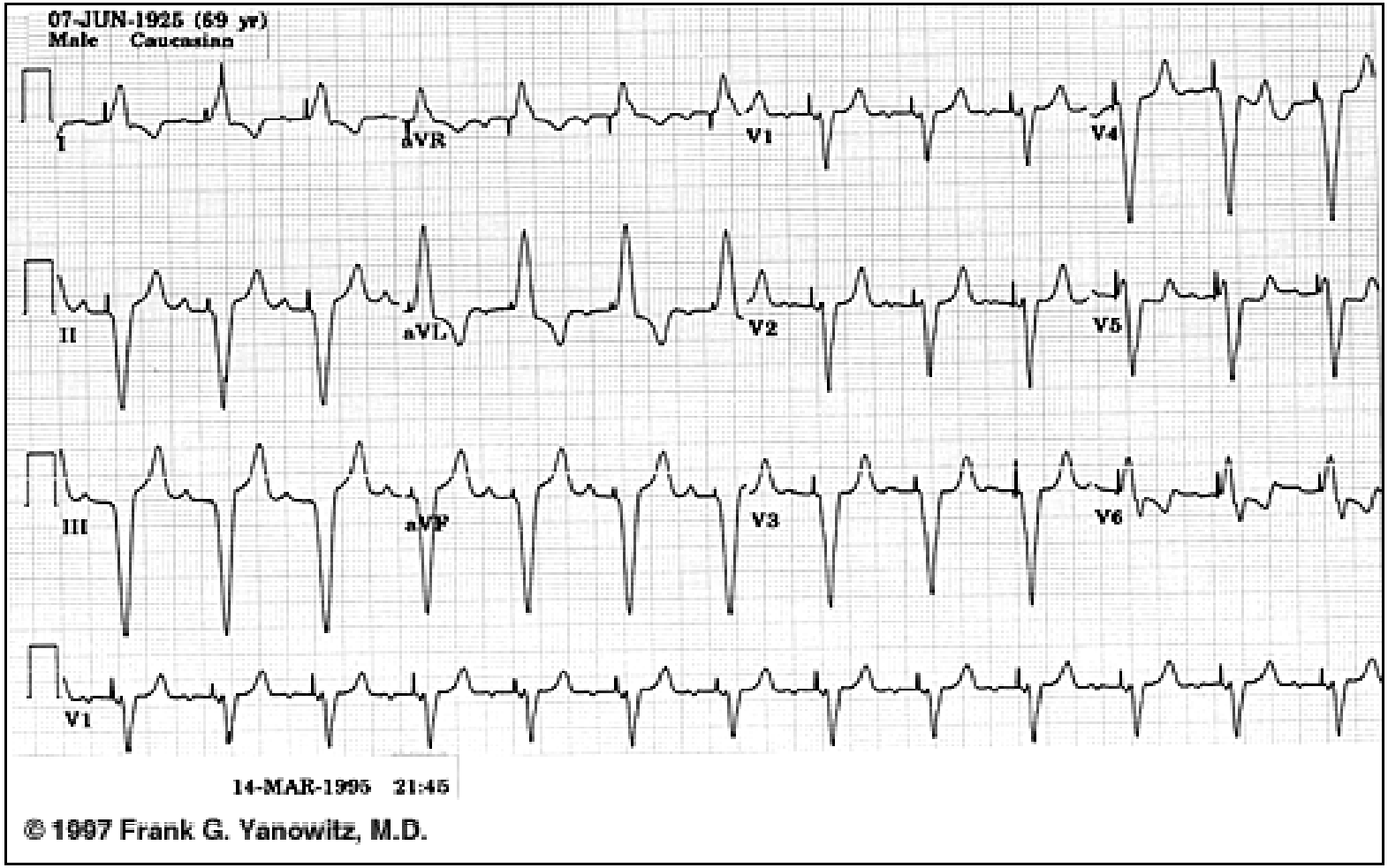

Kalp pili olan hasta
(VDD: atriyum sense-ventriküler pace)

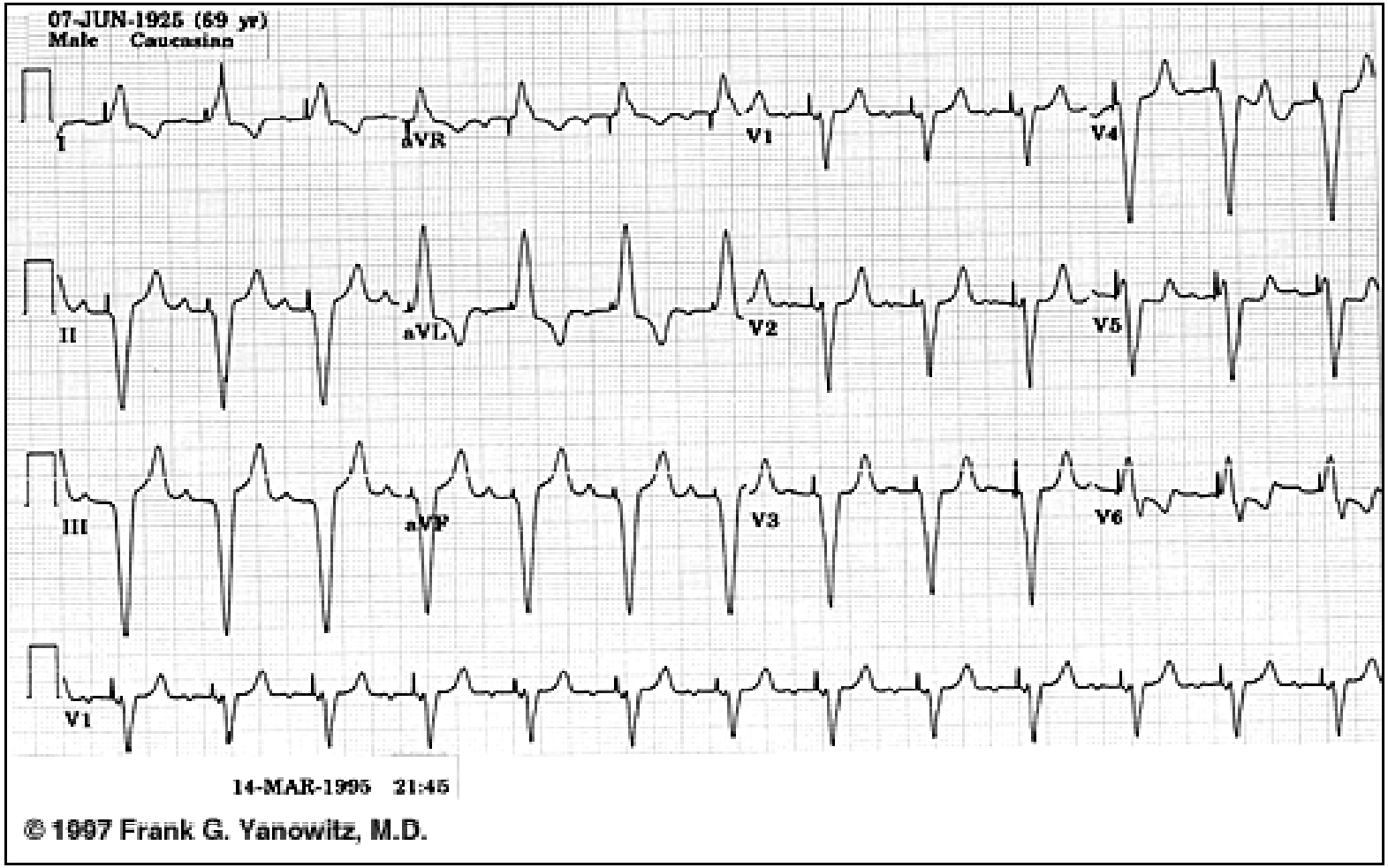

Tanınız nedir ?

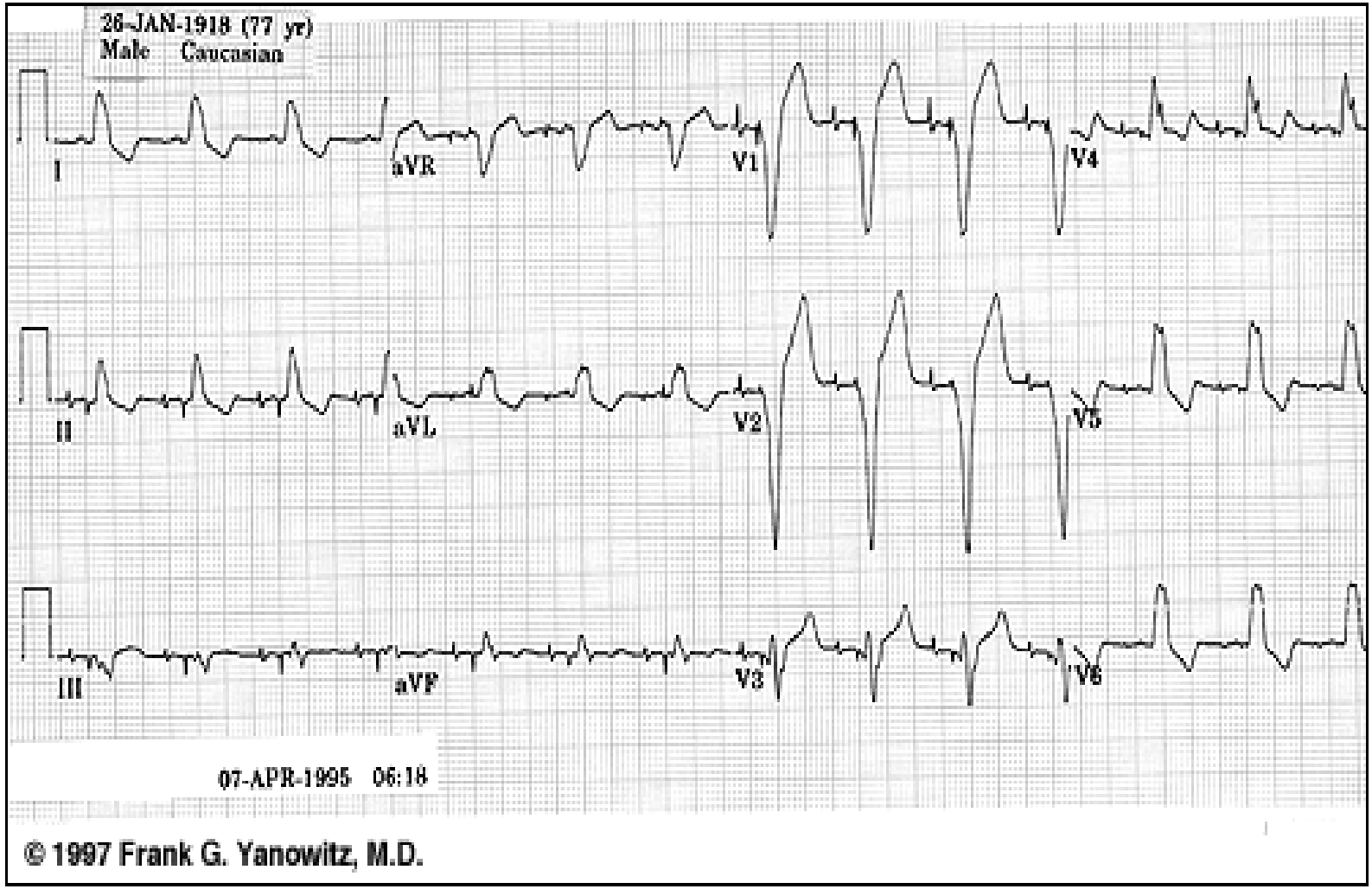

Kalp pili ona hasta
(DDD: atriyal pace-ventriküler pace)

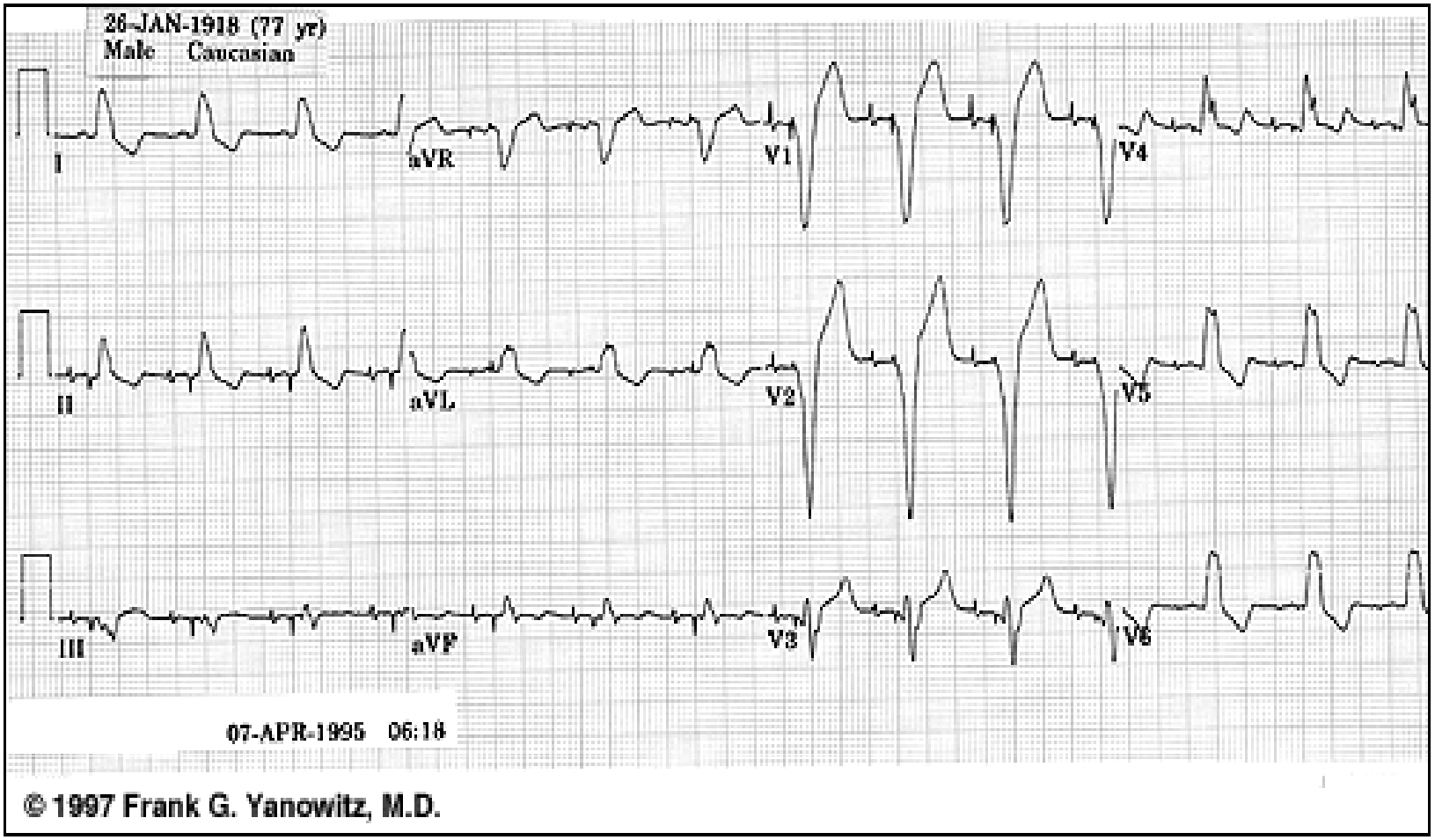

Tanınız nedir ?

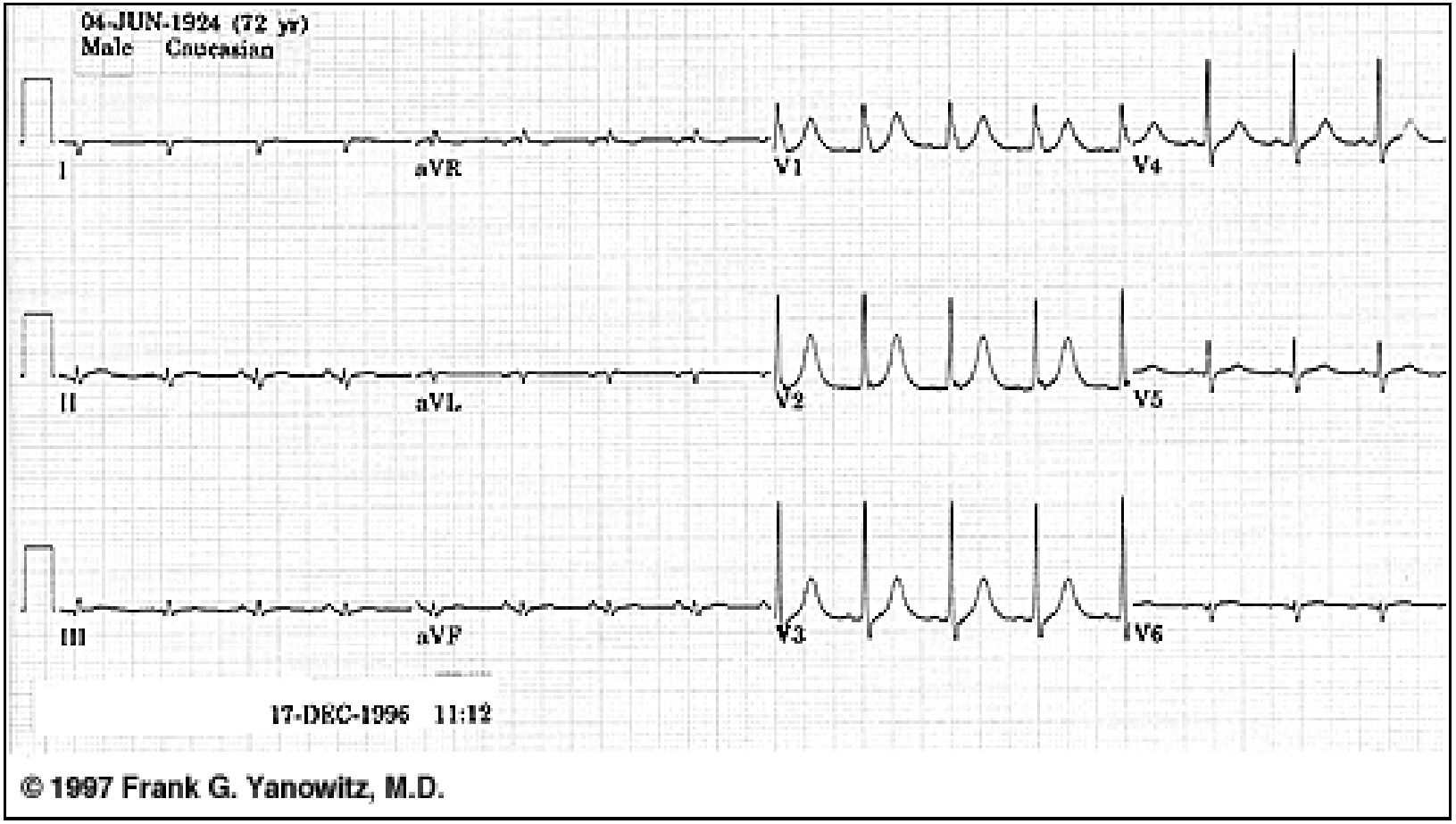

Geçirilmiş (eski) posterolateral MI

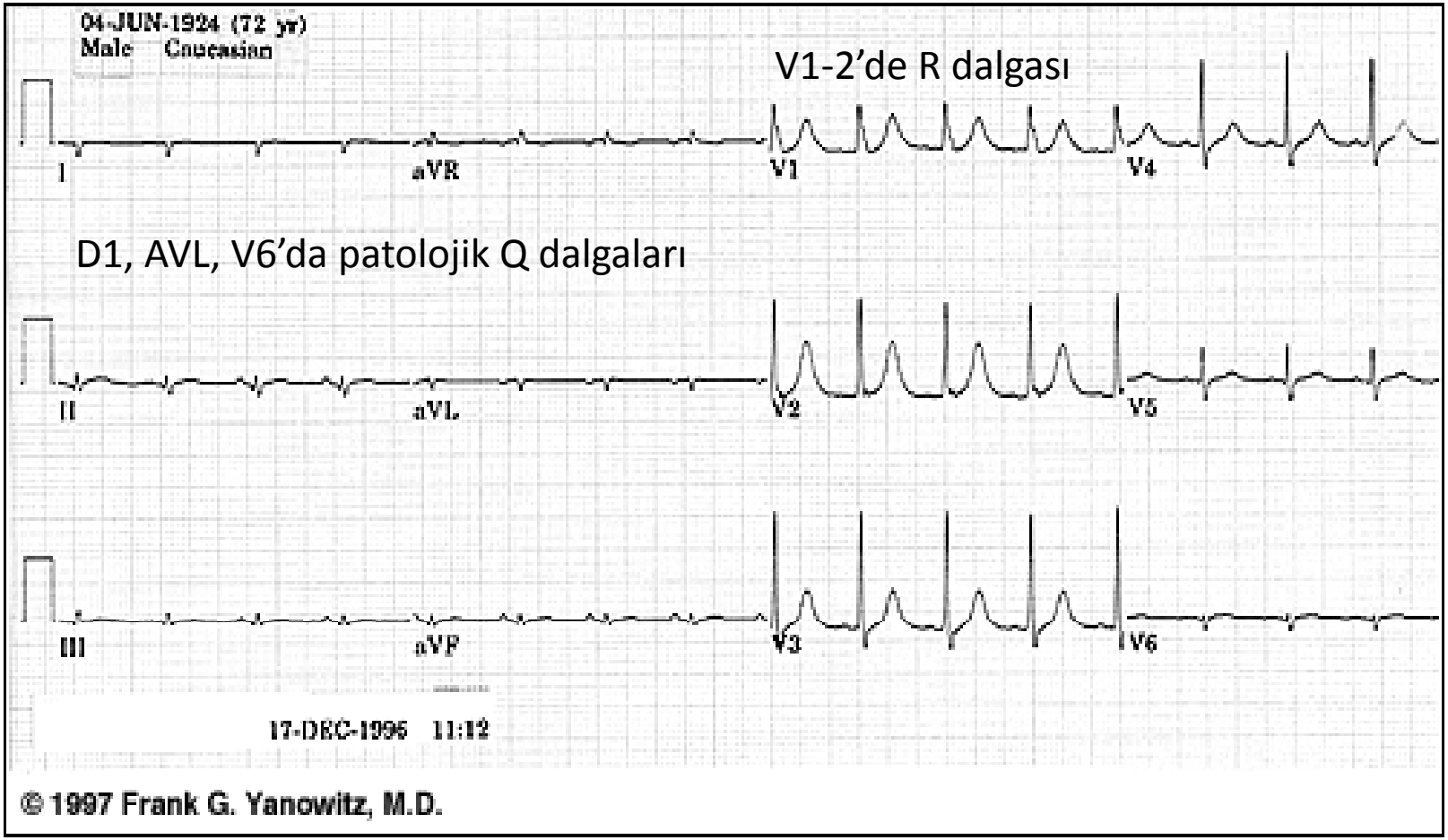

Tanınız nedir ?

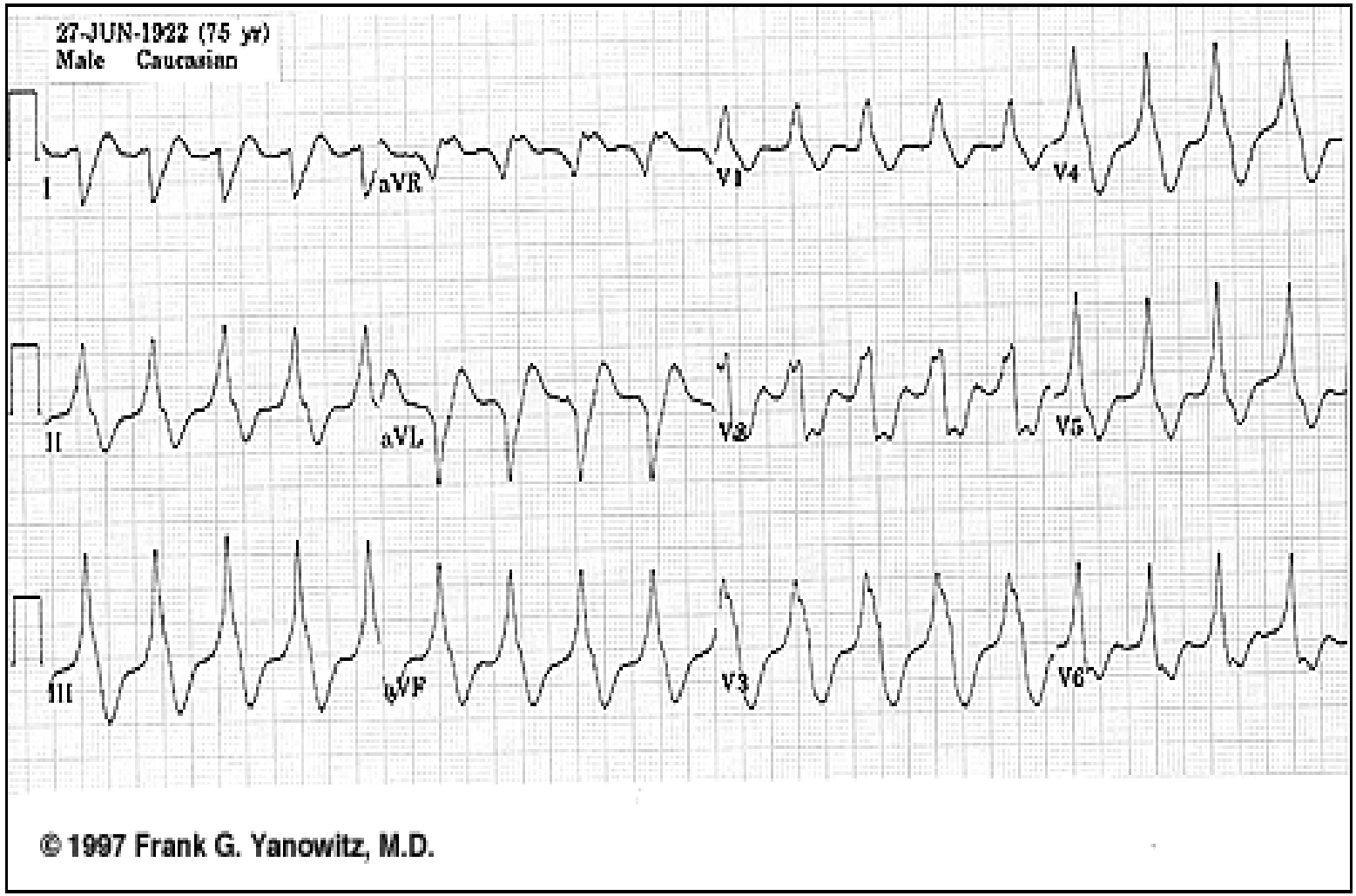

Ventriküler Taşikardi
(prekordiyal derivasyonlarda konkordans mevcut)

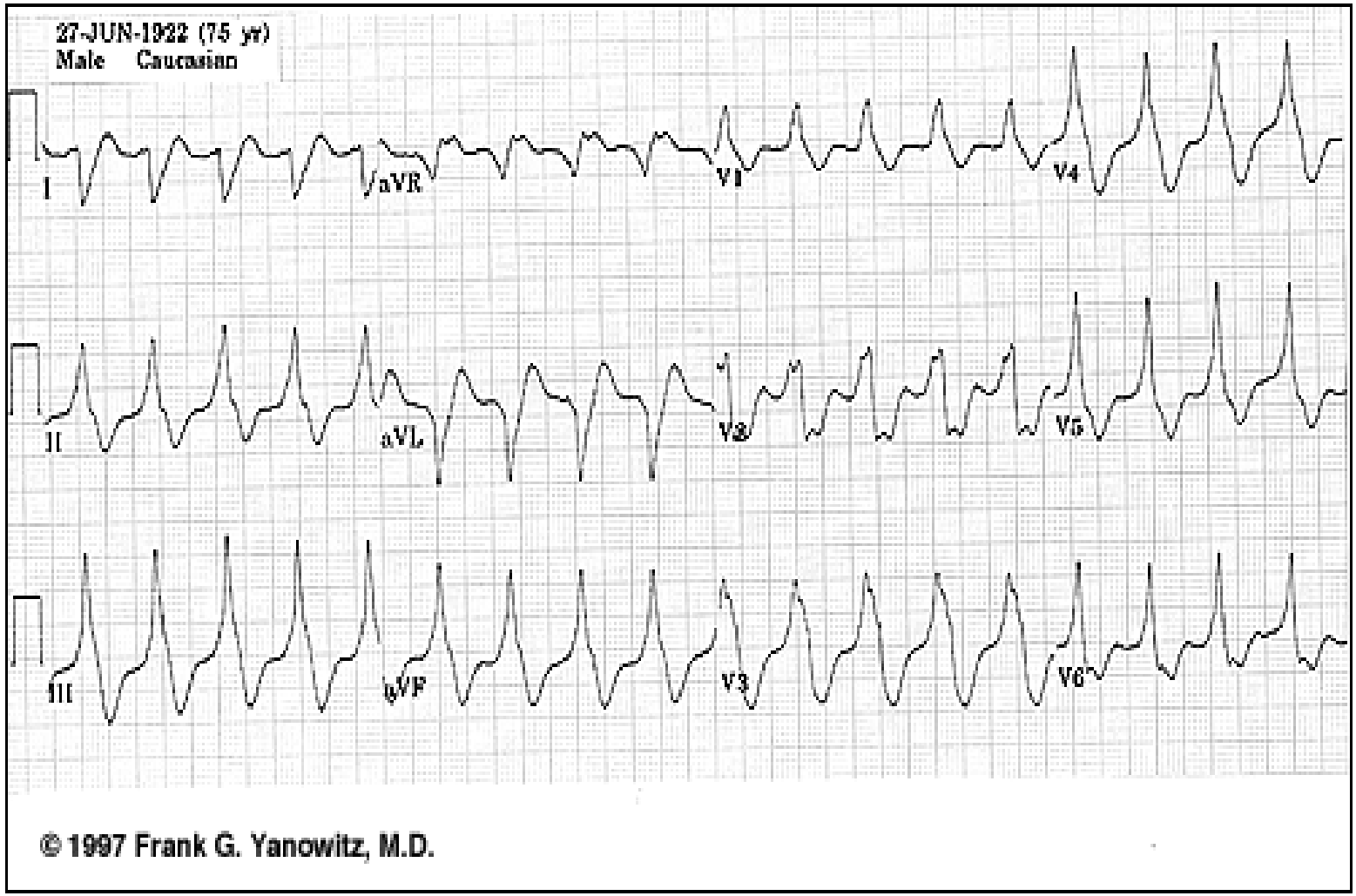

Tanınız nedir ?

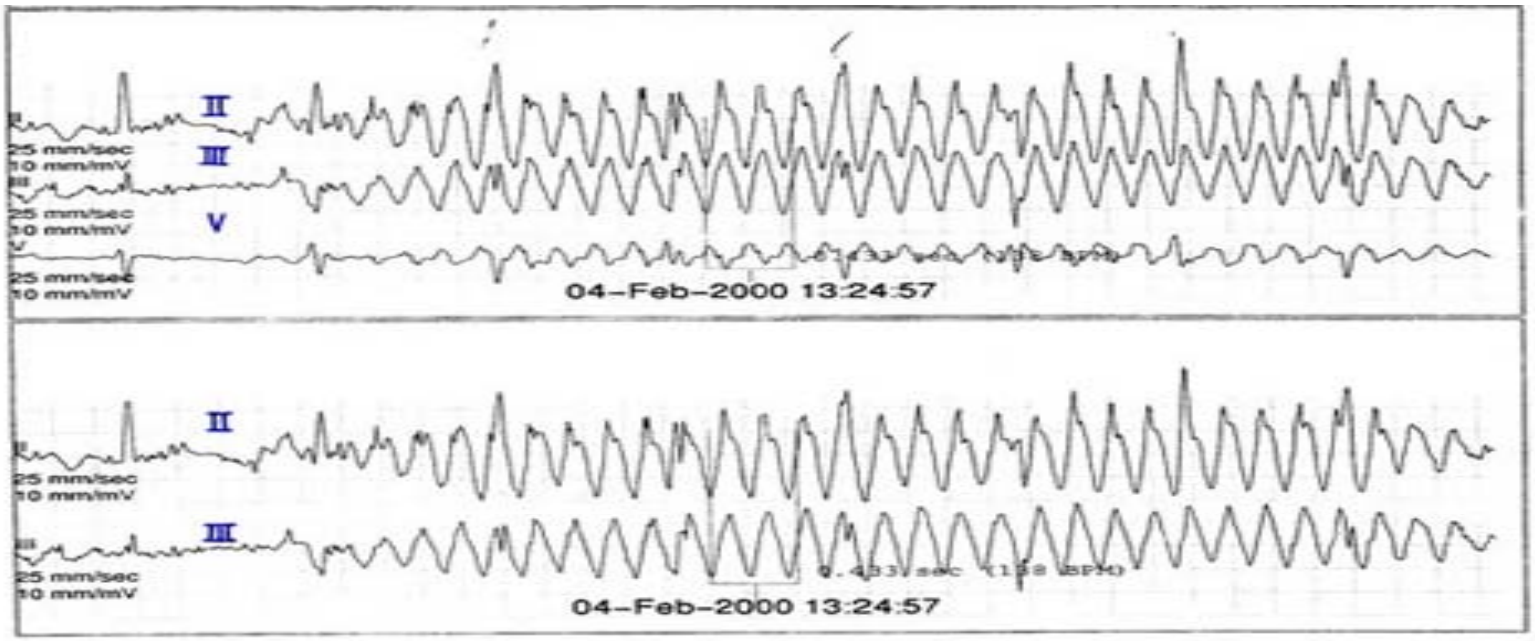

Torsades de Pointes (Polimorfik ventriküler Taşikardi)

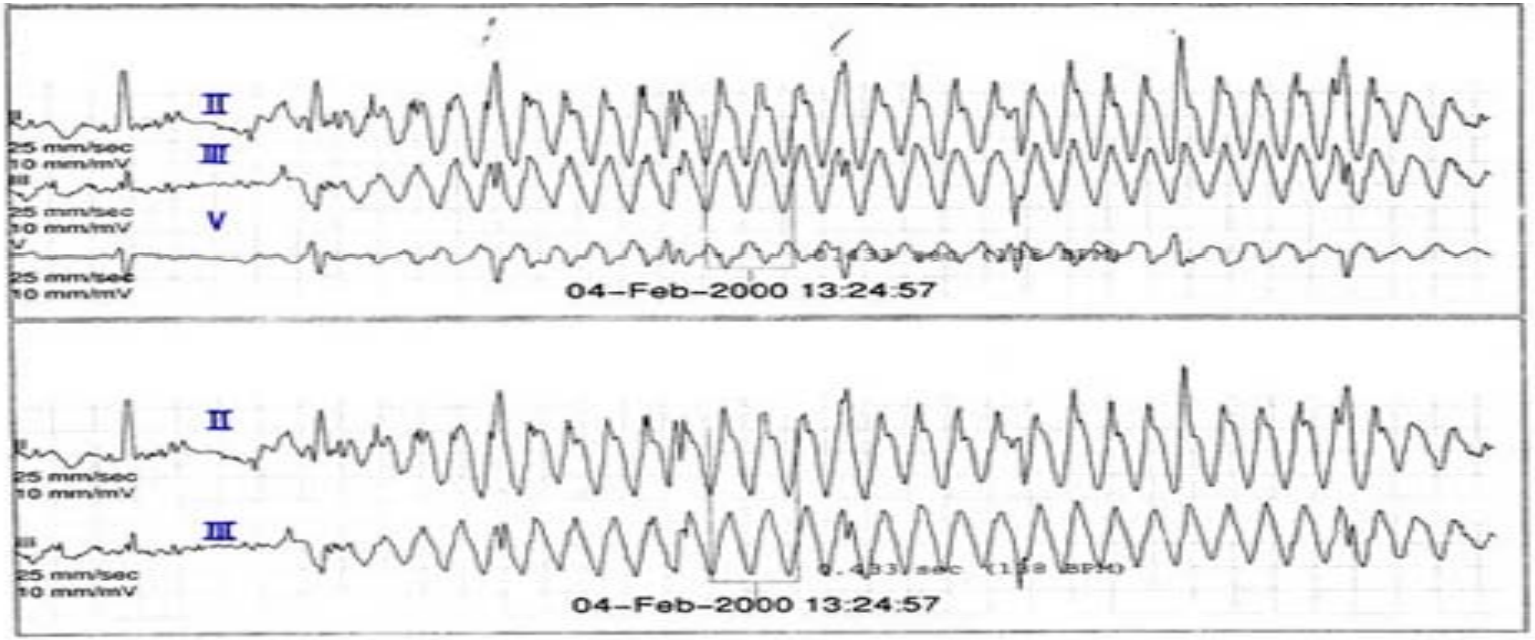

Tanınız nedir ?

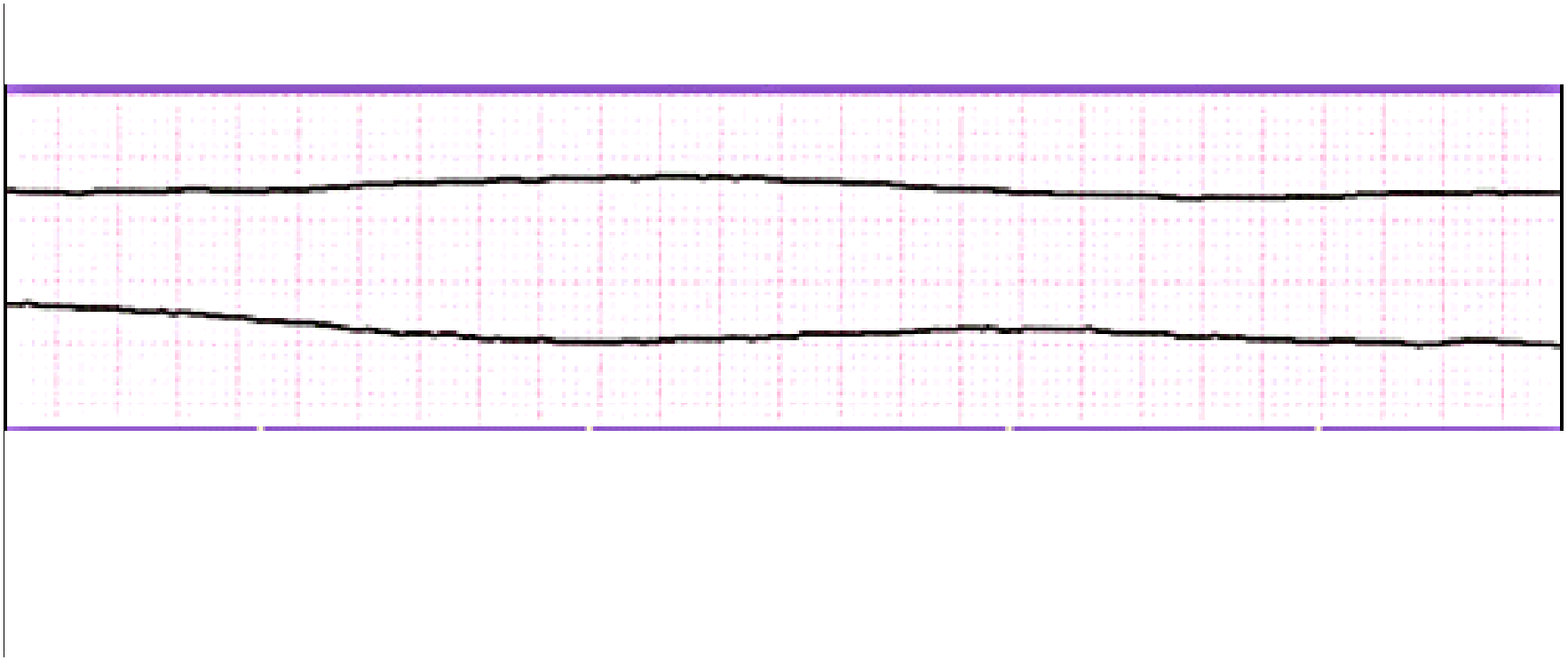

Asistoli



Heart Rate	Rhythm	P Wave	PR interval (in seconds)	QRS (in seconds)
Absent	Absent	Absent or present	N/A	Absent